



End Violence Against Women International
(EVAWI)

Forensic Examinations of Sexual Assault Victims and Suspects

Role of the Examination in Sex Crimes Investigations

Part I: Types and Purposes of Evidence

Sergeant Joanne Archambault (Ret.)
Kimberly A. Lonsway, PhD
Kristin Littel

March 2019

This module is part of EVAWI's OnLine Training Institute (OLTI), which is available at no cost, and includes review exercises, practical applications, and an end-of-course test. Participants can download a personalized certificate of completion to use for continuing education or other purposes. For more information, please see the [EVAWI website](#).

This project is supported by Grant No. 2017-TA-AX-K038 awarded by the Office on Violence Against Women, US Department of Justice. The opinions, findings, conclusions, and recommendations expressed in this publication/program are those of the authors and do not necessarily reflect the views of the Department of Justice, Office on Violence Against Women.

Table of Contents

Public Domain Notice	6
Electronic Access	6
Recommended Citation	6
Authors	7
Acknowledgements	8
Photo Credits	9
Objectives	10
About the Module	11
Purpose and Goal	11
Scope and Overview	11
Intended Audience	11
Organizational Features	12
Introduction	14
Missed Opportunities for Justice	14
Obtaining Physical Evidence	14
Incorporating Evidence into an Investigation	15
Goals of the Forensic Examination	16
Victim Examinations	16
Suspect Examinations	17
Not Just DNA Evidence	22
Case Example	22
Multidisciplinary Coordination for Examinations	24
Forensic Examiners	24
Law Enforcement Involvement	24
VAWA Forensic Compliance	25
Pre- and Post-Exam Consultation	26
Clarify Discrepancies in Documentation	27
Update Crime Scene Personnel	28
Implementation Guidance in Part II of Module	28
Managing Forensic Exam Records and Photographs	29
Standardized Reporting Forms	29
Storage of Victim Records and Photographs	30
Suspect Records and Photographs	34



Responding to a Subpoena	34
Purposes and Types of Evidence.....	35
Scope of Evidence.....	36
Physical Findings.....	36
Evidentiary Samples	37
Investigative Purposes.....	38
Identify or Exclude Suspects	39
Document Evidence of Recent Sexual Contact	41
Document Evidence of Force, Threat, Fear, or Incapacitation.....	42
Corroborate Statements of Victims, Suspects, and Witnesses.....	43
Case Example	45
Initial Focus on the Victim’s Account	46
Types of Evidentiary Samples and Items	48
Documented Statements, Behaviors, and Demeanor.....	48
Foreign Material on/in Body Surface and Orifices	49
Body Surface Swabs.....	49
Semen/Seminal Fluid.....	52
Recovery of Semen Over Time.....	53
Saliva.....	54
Blood Evidence.....	55
Hair Evidence	56
DNA Reference Standards	57
Clothing Evidence.....	58
Items Collected with Clothing.....	60
Photographic Evidence.....	61
Toxicological Samples.....	62
Examples of Potentially Probative Evidence.....	65
Identification and Documentation of Injury	66
Nongenital Injuries.....	66
Location of Nongenital Injuries.....	67
Prevalence of Nongenital Injuries.....	67
Patterned Nongenital Injuries.....	68
Genital Injuries.....	71
Location of Genital Injuries.....	71
Prevalence of Genital Injuries	72



Factors that Impact Genital Injury Identification	74
Does Genital Trauma “Prove” Sexual Assault?.....	75
What if There are No Injuries?	76
Conclusions from Victim and Suspect Examinations	77
Victim Examinations	77
Suspect Examinations	79
Law Enforcement Documentation of Exam Findings.....	79
Transportation by Patrol	80
Investigator’s Follow-Up Documentation	80
Documentation of Injuries and Medical Treatment.....	81
Medical Forensic Examination and Evidence	82
Examination of an Adult with an Intellectual Disability	83
Which Evidence is Likely to be Most Probative?	84
Practical Application: Case Study Analyses.....	85
Case Study #1: Forcible Rape of a 16-Year-Old Female by a 28-Year-Old Male Soccer Coach	86
Collecting Victim Clothing	89
Investigator Assessment.....	90
Prioritizing Items for Analysis	92
Laboratory Findings	93
Testing Process	93
Case Study #2: Forcible Rape, Digital Penetration, and Oral Copulation of a Female by Two Male Suspects.....	94
Investigator Assessment of Suspects’ Forensic Examinations	99
Case Study #3. Suspected Drug-Facilitated Sexual Assault of a Female by One or More Male Fraternity Members.....	105
Case Study #4: Forcible Rape and Sodomy by a Male Who Met a Female at a Party and Offered Her a Ride Home	112
Case Study #5: Attempted Sexual Assault of a Female by a Male Stranger in a Park	116
Case Study #6: Forcible Oral Copulation of 22-Year-Old Male by a Male Acquaintance.....	119
Conclusion	124
Appendix A. Purposes of Common Evidentiary Samples.....	125
Appendix B. Female and Male Genital Anatomy Illustrations.....	128
Appendix C: Examples of Nongenital Physical Findings.....	129



Appendix D: Anatomy Evaluated During Genital Examination	130
Appendix E. Sample Investigator Follow-Up Reports.....	131
Appendix F. Case Study Materials	132
Appendix G: Blank Case Study Forms and Other Tools	133
References.....	134



Public Domain Notice

Unless something is excerpted directly from a copyrighted source, all the material in this document is in the public domain and may be reproduced or copied without specifically requesting permission from End Violence Against Women International (EVAWI) or the authors. Any direct quotes or excerpts should be properly cited, however. No one may reproduce or distribute this material *for a fee* without the specific, written authorization of End Violence Against Women International (EVAWI).

Electronic Access

The publication may be downloaded from End Violence Against Women International's [Resource Library](#).

Recommended Citation

Archambault, J., Lonsway, K.A., Littel, K. (2019). *Forensic Examinations of Sexual Assault Victims and Suspects: Part 1*. End Violence Against Women International.



Authors

Joanne Archambault (Retired, San Diego Police Department) is the Chief Executive Officer for EVAWI. Prior to founding EVAWI in 2003, Sgt. Archambault worked for the San Diego Police Department for almost 23 years, in a wide variety of assignments. During the last 10 years of her service, she supervised the Sex Crimes Unit, which had 13 detectives and was responsible for investigating approximately 1,000 felony sexual assaults each year. Sgt. Archambault has provided training for tens of thousands of practitioners, policymakers, and others – both across the country and around the world. She has been instrumental in creating systems-level change through individual contacts, as well as policy initiatives and recommendations for best practice.



Dr. Kimberly A. Lonsway is a Founding Director and has served as the Director of Research for EVAWI since 2004. Her research focuses on sexual violence and the criminal justice and community response system, and she has written over 60 published articles, book chapters, technical reports, government reports, and commissioned documents – in addition to numerous training modules, bulletins, and other resources. Over her career, she has trained thousands of professionals across the country and around the world, in a diverse array of disciplines and settings, and volunteered for over 15 years as a victim advocate; in 2012, she was awarded the first-ever Volunteer of the Decade Award from the Sexual Assault Recovery and Prevention (SARP) Center in San Luis Obispo, CA. She earned her PhD in the Department of Psychology at the University of Illinois, Urbana-Champaign.



Kristin Littel, an independent consultant since 1996, creates technical assistance and training products related to intervening in and preventing sexual assault, dating and domestic violence, and stalking. To date, she has consulted on over 50 projects, in collaboration with approximately 25 organizations. Ms. Littel was drawn into efforts to address interpersonal violence in the early 1990s, after earning her MA from the Department of Education at the University of Maryland, College Park, and working in college student personnel services. She served in direct service and/or leadership positions at numerous regional sexual assault victim advocacy programs – in Cincinnati, OH (volunteer), Yakima, WA (Assistant Coordinator), Richmond, VA (volunteer), and Fredericksburg, VA (Executive Director). She also was a member of multiple boards and councils that promoted community engagement, service, and collaboration to address social justice issues, including child abuse and sexual assault.



Acknowledgements

We are extremely grateful to the following individuals (listed in alphabetical order), for their valuable contributions to the development of this training module:

- Kathy Bell, MS, RN, Forensic Nursing Administrator, Tulsa Police Department, Tulsa, OK
- Ann Burdges, Board President, EVAWI, Consultant / Trainer, Atlanta, GA
- Kim Day, RN, SANE-A, SANE-P, Forensic Nursing Director, International Association of Forensic Nurses, Elkridge, MD
- Elizabeth Donegan, Director, EVAWI, Sergeant (Ret.), Austin Police Department, Austin, TX
- Diana Faugno, MSN, RN, CPN, SANE-A, SANE-P, FAFS, DF-IAFN, DF-AFN, President and Co-Founder, Academy of Forensic Nursing, Treasurer and Founding Director, EVAWI, Dallas, GA
- Catherine Johnson, Secretary, EVAWI, Law Enforcement Specialist (Forensics / Investigative Instructor), Investigative Operations Division / Forensics and Special Investigative Skills Branch, Federal Law Enforcement Training Center, Glynco, GA
- Rich Mankewich, Director, EVAWI, Sergeant, Sexual Offender Surveillance Squad, Orange County Sheriff's Office, Orlando, FL
- Stacey Mitchell, DNP, MBA, RN, SANE-A, SANE-P, DF-AFN, FAAN, Clinical Associate Professor, Texas A&M University, Director, Academy of Forensic Nursing, Associate, EVAWI, Bryan, TX
- Valerie Sievers, MSN, RN, CNS, SANE-A, SANE-P, DF-AFN, Forensic Clinical Nurse Specialist, Forensic Healthcare Consultant, Director, Academy of Forensic Nursing, Peyton, CO
- Gael Strack, CEO and Co-Founder, Alliance for Hope International and the Training Institute on Strangulation Prevention, Adjunct Law Professor, California Western School of Law, San Diego, CA



Photo Credits

Unless otherwise indicated, the photographs in this module were provided by the [Academy of Forensic Nursing](#) (AFN). The AFN advances nursing providers, educators, scholars and researchers committed to the development, implementation and evaluation of the specialty of forensic nursing. The AFN is dedicated to fostering knowledge, skills, attitudes, and clinical competencies, through mentorship of professionals and by building partnerships, disseminating scholarship and research to direct practice globally, improving the lives of those affected by trauma.



Objectives

At the end of this training module, the learner will be better able to:

- Explain the primary goals of a forensic examination conducted with a victim or suspect in a sexual assault investigation.
- Describe the full scope of evidence that may be identified, documented and collected during a forensic examination of a sexual assault victim or suspect.
- Articulate the investigative purposes of evidence collected and documented during the forensic examination of a sexual assault victim and suspect.
- Discuss the importance of the victim's history of the assault to the investigation.
- Explain the need for law enforcement professionals to communicate with forensic examiners and crime scene technicians to maximize evidence collected and documented, and to address any documentation discrepancies.
- Discuss how different types of evidence can help establish the elements of the crime, corroborate or challenge statements made by a victim, suspect, or witnesses, and address potential defenses.
- Describe the investigative value of documenting statements, observable behaviors, and demeanor of victims and suspects during forensic examinations.
- Explore the investigative value of photographic evidence, including photographs of genital and nongenital injuries.
- Explain what can and cannot be concluded on the basis of a forensic examination of a sexual assault victim or suspect.
- Practice documentation of examination findings for law enforcement purposes.
- Discuss investigative decision-making regarding what evidence collected or documented in a sexual assault investigation is likely to be the most probative.
- Apply newly acquired knowledge regarding the investigative uses of evidence collected and documented during forensic examinations via case study activities.



About the Module

Purpose and Goal

The purpose of this module is to improve the use of forensic examinations to collect evidence from the bodies and clothing of both victims and suspects during a sexual assault investigation. The module goes beyond simply explaining the procedures that are used during victim and suspect forensic examinations. It also explores the different types of evidence that may be gathered during these examinations and describes how this evidence can be used to advance a sexual assault investigation. It also gives participants an opportunity to apply what is learned through case study activities.

Ultimately, the goal of this module is to encourage professionals involved in these cases to push past traditional ways of thinking about evidence, to critically analyze how each piece of information gathered fits into the complicated puzzle of a comprehensive investigation.

Scope and Overview

This module focuses exclusively on sexual assaults committed against adults and adolescents; it does not address issues pertaining to child victims. This is true for a variety of reasons, including the stated purpose of EVAWI's grant funding from the Office on Violence Against Women (OVW), US Department of Justice, which is to improve the criminal justice response to adult and adolescent sexual assault.









In Part I of this module, we focus on the types and purposes of evidence collected and documented during victim and suspect forensic examinations. In Part II, more detailed information is provided about the exam process, including logistical and policy issues.

Intended Audience

Because the purpose of the module is to improve the use of forensic examinations of victims and suspects during a sexual assault investigation, it is primarily intended for criminal justice professionals, such as investigators and prosecutors, as well as forensic examiners. However, we also hope it is useful for other professionals involved in sexual assault responses and the criminal justice process. This includes health care providers (particularly those who conduct forensic examinations), victim advocates, and other social service providers. It could also be beneficial for professionals who have a stake in the design and implementation of these forensic examinations (e.g., educators, policymakers).

Organizational Features

Throughout this module, we use several tools to help readers understand how evidence gathered during victim and suspect forensic examinations fits into the broader context of a successful law enforcement investigation. They are indicated with the following icons:

- | | |
|--|--|
|  Research studies and case examples |  Information to note |
|  Innovative and promising practices |  Questions for participants |
|  Resources and tools |  Interactive exercises |
|  Instructional video clips |  Policy recommendations |

Explanation of a Few Terms

- In this module, we sometimes say “forensic examination” (or “forensic exam”), or simply “examination” (or “exam”), to refer to the sexual assault medical forensic examination of a victim or the forensic examination of a suspect. By dropping the word “medical” from forensic examinations of victims, we are in no way diminishing the importance of victim medical care; it is simply used for grammatical simplicity to include both victim and suspect examinations. The nature of the suspect examination is almost exclusively forensic, not medical.
- When we refer to the “examination (or exam) process,” we mean the logistical components such as timing, coordination, and examination steps. Victim and suspect examinations have similar as well as distinct process components.
- We use the term “victim” to describe someone who discloses sexual assault victimization, in the context of their possible involvement with the criminal justice system.¹ This is because “victim” is a term of art used at every stage of the criminal justice process. Other terms are used by other professional disciplines. For example, those in the health care profession generally use “patients” to refer to victims who present to them. Victim advocates and other social service providers may use “survivors,” “clients,” or other terms.
- When referring to the criminal justice system, we describe people who are accused of sexual assault using their specific legal standing – “suspects” prior to the filing of charges, and “defendants” during the pendency of a criminal prosecution and trial. More generally, “perpetrators” or “assailants” are used

¹ When we use singular pronouns in this module, we use “he,” “him,” and “his” for males, and “she,” “her, and hers” for females. However, a growing number of people, especially those from the transgender community, refer to themselves using gender-neutral or alternative pronouns such as “ze,” “xe,” and the singular “they.” Some individuals may also use names and pronouns that are different from what is listed on their identification or insurance documents. In professional practice, we encourage use of a person’s preferred pronoun. For more information, see FORGE’s 2-page [FAQ: Pronouns and Trans Individuals](#).

to refer to those who commit sexual assault. Health care providers who conduct forensic examinations of suspects may refer to them as “patients.”

- Finally, we use the term “investigator” to refer to law enforcement personnel who have responsibility for conducting sexual assault investigations. In smaller agencies, this may be a patrol officer, whereas larger agencies may have detectives assigned to a General Investigations Unit, or a specialized Sex Crimes or Special Victims Unit. We also recognize that law enforcement agencies use different terms for their sworn personnel, including officers, deputies, troopers, etc. However, for the purpose of this module we will use the term “investigator” to generally refer to sworn law enforcement personnel (or non-sworn campus security) who investigate sexual assault reports.
- For further explanation of sexual assault medical and forensic terminology, two references include [The Prosecutor’s Reference: Medical Forensic Examination and the Role of SANEs in Cases Involving Adult Victims](#) (pp. 10-25) and the [Biological Evidence Preservation Handbook](#) (pp. 57-60). It is important that investigators build their familiarity with these terms, to effectively communicate with other responding professionals and explain the evidence documented in investigative reports.



We also encourage a review of EVAWI’s 5-page Training Bulletin, entitled [Words Matter: Suggested Guidelines on Language Use for Sexual Assault](#), to help responding professionals (1) maximize language accuracy in these cases, and (2) avoid language that can create confusion, perpetuate misinformation, and contribute to a climate of unwarranted skepticism and victim blaming.



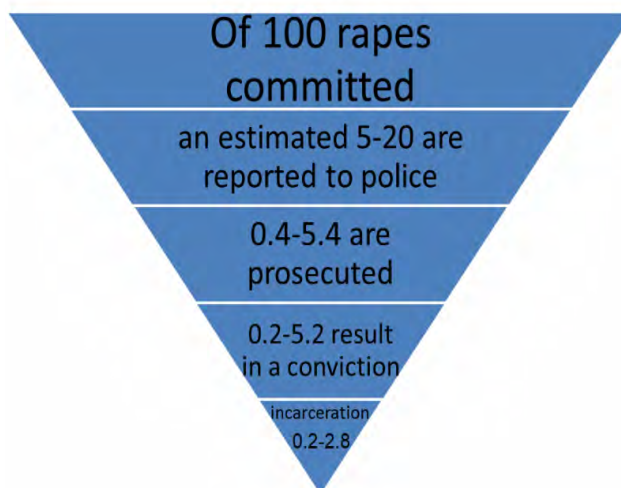
What is your motivation for completing this module? How do you hope to apply the information gained to your daily work?



Introduction

Missed Opportunities for Justice

Within the US, as in many other countries, the criminal justice response to sexual assault is all too often characterized by missed opportunities. As illustrated with this graphic, attrition rates are very high; of 100 forcible rapes that are committed: an estimated 5 to 20 will be reported; 0.4 to 5.4 will be prosecuted; 0.2 to 5.2 will result in a conviction; 0.2 to 2.9 will yield a felony conviction; and 0.2 to 2.8 will result in incarceration of the defendant, with 0.1 to 1.9 in prison and 0.1 to 0.9 in jail (Lonsway & Archambault, 2012).² Such high rates of attrition limit victims' ability to pursue justice and healing. Also, because perpetrators often re-offend, this leaves communities vulnerable to continued violence.



Why is attrition so high for sexual assault?
What makes these cases so difficult to successfully investigate and prosecute?

One factor is the difficulty in proving the legal elements of sexual assault beyond a reasonable doubt. For example, many people assume that these cases are prosecuted solely on the basis of statements provided by the victim and suspect, without any physical evidence (often characterized as “he said, she said” cases). However, physical evidence can often be obtained in sexual assault cases, if investigators know where it might be found and how it can meaningfully advance the investigation.

Obtaining Physical Evidence

Physical evidence is often collected and documented at the scene of a crime, with the goal of determining what happened and identifying or excluding suspects. This is true for any type of criminal investigation, not just sexual assault (e.g., robbery, homicide, intimate partner violence, etc.). In sexual assault cases, the body and clothing of both the victim and suspect sometimes offer additional sources of physical evidence. But it is important to remember that this is not the only – or even the most important – source of evidence in these cases. The significance of exam evidence can only be understood within the context of other evidence, including statements provided by the victim, suspect, and any witnesses, and physical evidence from a variety of other sources.

² The graphic is drawn from Lonsway and Archambault (2012, p.157). McEwen (2011) and Spohn & Tellis (2012) offer additional data on sexual assault case attrition in the US criminal justice system.

Incorporating Evidence into an Investigation

To increase the likelihood that a sexual assault case can advance to prosecution where the facts and evidence warrant, investigators not only need to know *how* to obtain exam evidence, but also *what to do with it once obtained*. This requires:

- Learning how each type of exam evidence can contribute to the investigation.
- Becoming familiar with the policies and procedures for collecting exam evidence from victims and suspects and requesting laboratory analyses of that evidence.
- Learning terms related to the medical forensic examination, including the body and how it functions, and being able to accurately explain exam findings.
- Building skills in assessing exam evidence, to help corroborate or dispute known case facts, and guide investigative strategies.
- Assessing the totality of evidence and information gathered in a sexual assault case, to inform investigative strategies and decisions.



This module focuses on the role that evidence collected and documented during forensic examinations can play in sexual assault investigations. It is not designed to guide patient care. For technical guidance on how to conduct exams, and to enhance coordination across disciplines, several resources are available:

[National Protocol for Sexual Assault Medical Forensic Examinations – Adult/Adolescent](#) (2nd ed., 2013). Office on Violence Against Women, US Department of Justice. (We refer to this as the “National Protocol.”)

[A National Protocol for Sexual Abuse Medical Forensic Examinations – Pediatric](#) (2016). Office on Violence Against Women, US Department of Justice. (In this module, this is called the “National Protocol – Pediatric.”)

[Evaluation and Management of the Sexually Assaulted or Sexually Abused Patient](#) (2nd ed., 2013), American College of Emergency Physicians.

[National Best Practices for Sexual Assault Kits: A Multidisciplinary Approach](#) (2016). National Institute of Justice, US Department of Justice and Sexual Assault Forensic Evidence Reporting (SAFER) Working Group.



Goals of the Forensic Examination

Victim Examinations

In the aftermath of a sexual assault, a medical forensic examination of the victim serves two main goals. One goal is medical: During the exam, victims are medically evaluated, treated for injuries, and related health needs and concerns are also addressed, including the risk of pregnancy or sexually transmitted infections (STIs). The other goal is to collect and document evidence for investigative purposes: Physical findings from victims' bodies and clothing can be documented, and evidentiary samples and items can be collected. Informed consent must be provided for the medical forensic exam by the victim (or the victim's guardian), and they can withdraw their consent to any or all procedures at any time. In Part II of this module we will provide detailed information on the exam process, policies, and protocols, including those addressing informed consent.

Some refer to sexual assault victims as “walking, talking crime scenes,” and this characterization is supported by the research. In one early study, sexual assault cases were about twice as likely to be prosecuted if the victim had a medical forensic examination (Lindsay, 1998). Other studies document that medical forensic examinations of victims, when conducted by trained examiners, result in an increase in sexual assault charges filed, sexual assault conviction rates, and respective average sentences (Campbell, Bybee et al., 2014; Campbell, Patterson & Bybee, 2012; Crandall & Helitzer, 2013).

A timely, high-quality medical forensic examination can potentially validate and address victims' concerns, minimize the trauma they may experience, and promote their healing. From a criminal justice perspective, the examination can increase the likelihood that evidence collected will aid in case investigation and help the case progress to prosecution, with the goal of perpetrators being held accountable and further sexual violence prevented.

National Protocol, p. 4



Conducting Investigations Without a Medical Forensic Examination

It is considered best practice to conduct a medical forensic examination with victims of a recent sexual assault, but the reality is that many victims do not obtain this type of care. In fact, estimates range from 19% to 40% for the percentage of victims who seek medical care of any kind following a sexual assault (Campbell, 2008; Kilpatrick et al., 2007; Zinzow et al., 2012). Of those who report their sexual assault to law enforcement, approximately half (44% to 55%) have a medical forensic examination (McEwen, 2011; Peterson et al., 2010). Thus, it is important to implement community practices that encourage victims to seek medical forensic care. However, investigators can proceed very

effectively without evidence from an exam, and policies and practices must be created to serve victims regardless of whether they have an exam or not.

Suspect Examinations

In contrast with the medical forensic examination of a sexual assault victim, the forensic examination of a sexual assault suspect generally focuses on forensic purposes, not medical purposes. The goal is to identify and document any injuries or anomalies, and to collect and document biological and trace evidence. There are exceptions, however, where the suspect examination may include medical interventions.

For example, the suspect may have an injury resulting from the sexual assault, a medical condition (such as diabetes or hypertension), or an STI or another communicable disease that may put the victim, suspect, and the community at risk. How this is handled will depend on where the exam is being conducted and the pertinent medical-legal obligations and protocols.³ However, for the purpose of this module we are focused only on the forensic purposes of the suspect forensic exam.

Exam Location and Logistics

It is critical to ensure that suspect forensic examinations are conducted in a different location than medical forensic examinations of sexual assault victims. This is both to prevent additional trauma for the victim and to avoid cross contamination of the evidence. For example, the suspect exam might be conducted in the emergency room, while the victim's exam takes place in the area designated for medical forensic exams of victims.

If the suspect exam is being conducted at a medical facility, the suspect may be admitted as a patient to the hospital emergency room or clinic, and health care providers may offer a medical evaluation and possible treatment for an identified medical condition, if the suspect/patient consents. In this scenario, the suspect will have medical records associated with the contact, and the costs of any medical testing or treatment will be the responsibility of the suspect (or the suspect's private insurance). The medical records from the exam will follow standard medical facility's procedures.

If the suspect exam is conducted at a non-medical facility, such as a free-standing forensic examiner program, or at a police department (when the exam is conducted by a contracted forensic examiner), only the forensic evidence collection components will be conducted at the time of the exam. If the forensic examiner identifies any issues that might require testing or treatment (e.g., diabetes, hepatitis), the suspect will be

³ Suspects may be injured and require medical attention as a result of police contact (e.g., during an arrest or pursuit) or a defensive wound (although this is unusual). If this is the case, and the suspect needs emergency medical attention, law enforcement would typically call an ambulance or transport the suspect to an emergency department for evaluation and treatment. Many law enforcement agencies have contracts with county hospitals that provide emergency medical services for suspects in custody, or when a medical clearance is needed prior to booking a suspect in jail. In other words, a suspect would not be transported for a forensic examination prior to necessary medical treatment.

encouraged to seek medical care. Keep in mind that a suspect would not be transported for a forensic examination if they had injuries requiring immediate treatment.

Regardless of where the suspect exam is conducted, and by whom, the cost of the exam should be paid for by law enforcement, just like any other expense incurred as a result of a criminal investigation.

Legal Authority for Exam

There are typically three ways that a suspect exam (or DNA reference standard) can be authorized, depending upon state laws and law enforcement department policies:

- The suspect consents to a forensic examination;
- A suspect examination conducted incident to arrest; or
- A search warrant/ court order is obtained to collect evidence from the body and/or the clothing of the suspect.

Part II of this module will provide more detailed information on each of these options. However, this highlights the importance of having local protocols for conducting a forensic examination with a suspect who *does not consent* (an involuntary exam).

Involuntary Suspect Exams

Protocols are needed for involuntary suspect examinations, not just for sexual assault investigations, but other criminal offenses such as crimes against persons, child abuse and homicide. In some jurisdictions like California, people who have been placed under arrest do not have the right to refuse a forensic examination for the collection of physical evidence. Case law defining a "search incident to arrest" permits the search of an arrested person for evidence relevant to the crime for which they are suspected. If the suspect is in custody and is unwilling to consent to the examination, evidence such as dried secretions, foreign materials, swabs of the hands for gunshot residue, and blood samples for alcohol analysis can be collected from the person without a search warrant, and without the person's consent, if the law enforcement officer believes the delay necessary to obtain a court order would result in the possible loss or destruction of evidence. As a result of this case law, California law enforcement officers have been routinely facilitating suspect forensic examinations for decades, and most communities have protocols in place to obtain a suspect forensic examination.⁴

In most states other than California, a search warrant is required (at least in practice, even if it is not a legal requirement) to conduct a suspect forensic examination if the suspect does not consent.⁵ If a medical facility will not conduct a forensic examination without the suspect's consent when there is legal authority (e.g., incident to arrest in

⁴ Although suspects are not typically combative during an involuntary forensic exam, law enforcement is authorized to use force to obtain the exam, where there is legal authority to conduct it, as long as the level of force does not "shock the conscience of the court."

⁵ State of California, Office of Emergency Services, [OCJP 950 Form, Instructions](#) and [Protocol](#).



states like California, or a search warrant), the SARRT and law enforcement should work together to come up with another solution. For example, medical facilities might express concern that they will be sued if they conduct a forensic examination without the suspect's consent. Law enforcement and the County Prosecutor can reassure the facility that they are acting as an agent of law enforcement and as such, they are protected by the legal authority or a search warrant which means that a judge has authorized the collection of the forensic evidence.

Even with a search warrant or court order, hospital legal advisors and forensic examiners may require consent from suspects prior to evidence collection, because they believe it violates their professional code of ethics and standards of practice.

However, there are many scenarios where health care providers provide law enforcement with evidence collected from a suspect in a criminal investigation without their consent. For example, if a suspect is shot during the commission of a crime, that suspect will receive emergency medical treatment and a bullet or bullet fragment may be collected by health care providers during the course of providing that treatment. This evidence is routinely handed over to law enforcement without the consent of the suspect (patient), and in fact failure to do so could be considered obstruction of justice.



Exam Protocol is the Same

Regardless of how the legal authority is obtained to conduct a suspect forensic exam (whether based on the arrest of a suspect, suspect consent or a search warrant), the exam protocol remains the same.



Appendix G includes two templates for an affidavit and search warrant to obtain a suspect exam: a San Diego County [Template Affidavit and Search Warrant for a Suspect Examination](#) and a [King County Washington Template Affidavit to obtain a Search Warrant for a Suspect Exam](#).

Health Care Facilities Not Mandated to Collect Forensic Evidence from Suspects

It is also important for law enforcement to understand that the legal authority to conduct a suspect exam does not dictate *who collects the evidence*. Health care providers and facilities are not required by law to conduct suspect forensic exams, and there are no sanctions for them declining to do so. This just means the law enforcement agency will need to contract with another individual or agency to perform the suspect exam.

However, health care facilities such as hospitals are encouraged to assist with law enforcement investigations, if called upon. Local agreements are recommended to detail the policies and protocols governing the health care facility's involvement in procedures conducted to assist in a law enforcement investigation.

Unfortunately, there have been a few incidents where an investigator has arrested a medical provider for obstruction of justice after refusing to collect forensic evidence. There is no legal justification for arresting a medical professional in this scenario. If a health care provider or facility (such as a hospital) is unwilling to collect the evidence needed by law enforcement, it is recommended that all the law enforcement agencies in the county work together to establish a contract with an independent forensic examiner program to conduct these exams.



Location of Suspect Exams

Because the San Diego Police Department routinely conducts forensic examinations with sexual assault suspects who are contacted or arrested within a few days of the assault (depending on the case facts), the agency established a contract with an independent forensic examiner program to conduct suspect exams. Once the contract was established, smaller law enforcement agencies in San Diego County capitalized on the opportunity and followed the same procedures to conduct their own suspect forensic examinations.

The program ensured that two forensic examiners were on call to conduct suspect forensic exams 24/7/365. The forensic examiners performed the exams at the San Diego Police Department's Headquarters, the same location all suspects arrested by San Diego Police officers were transported to prior to booking a suspect in jail. This saved a great deal of time since the forensic examiners responded to the police department, and they impounded the evidence directly in the property room at Headquarters. Again, this meant the officers did not have to wait for the forensic examiner to complete the paperwork or package all the biological materials before transporting the suspect to jail. It also prevented the possibility of a suspect being examined in the same medical facility as the victim in the case, who might be having a medical forensic examination as well. This practice can add additional trauma to victims (even if it's not the suspect in their case but another suspect in handcuffs), and it can also create an opportunity for cross contamination of forensic evidence.

Law enforcement agencies that contract with a forensic examiner program follow procedures that are similar to how they might contract with phlebotomists to be on call or available to draw blood for suspects arrested for driving under the influence or other criminal offenses. What is important is that SARRTs recognize the value of suspect forensic examinations, and they work together with law enforcement to establish protocols that meet the needs of law enforcement and prosecutors while respecting the role of health care providers.

Importance of Suspect Examinations

Evidence collected from a suspect exam can often be critical in a sexual assault investigation. Suspects could potentially have evidence pertinent to the assault on their bodies and/or clothing. They may have physical injuries, anomalies, or clothing damage



that corroborates or refutes statements provided by the victim or suspect. Their statements, behaviors, and demeanor may also have value for the investigation. In other words, exam evidence might either support or challenge the theory that the suspect is in fact the perpetrator. A thorough suspect exam also demonstrates diligence on the part of the investigator, which is critical for juries considering the evidence.

Unfortunately, suspect forensic exams may be one of the most often overlooked sources of evidence in sexual assault investigations.



In this 1-minute [video](#), Sergeant Joanne Archambault (Retired, San Diego Police Department) emphasizes the value of suspect forensic examinations.

Any contact between two or more people will potentially involve a transfer of evidence from one to the other. When a sexual assault is reported, it can therefore be just as important to look for biological material or other evidence *from the victim* on the body or clothing *of the suspect*, as it is to look for biological material or other evidence *from the suspect* on the body or clothing *of the victim*. To illustrate, in a case involving digital penetration of a victim's vagina, rectum, or mouth, the suspect's fingers may be a valuable evidentiary source. Or, if a suspect forced his penis into the victim's mouth during an assault, his penis may be a richer source of evidence than the victim's mouth.

Suspect Exams Often Overlooked

Why are suspect exams overlooked in most protocols, despite other advances that have been made across the country? Some possible explanations include the following:

- Historically, investigators have not had the training and tools necessary to obtain search warrants for suspect exams where needed. As a result, many law enforcement agencies have limited the examination of a suspect to photographs and a few swabs taken by investigators or laboratory personnel.
- In addition, investigators have not always recognized the significance of evidence that can be collected and documented during a suspect exam. Yet it can potentially advance the investigation of a range of crimes against persons, especially those with physical contact between victims and suspects. This could include, for example, cases of child abuse, elder abuse, intimate partner violence, assault with a deadly weapon, or homicide. More research is needed to increase the understanding of which types of evidence may be found from which sources, and how long after an assault evidence can be recovered.
- There may also be a question about who pays for suspect exams conducted by a forensic examiner. However, law enforcement agencies should consider the suspect's forensic exam the same as any other type of evidentiary work, such as crime scene processing and associated laboratory expenses. Rarely does anyone question the costs that law enforcement agencies incur for evidence



collection in other investigations, such as bank robberies and automobile accidents (often investigated solely for insurance purposes), free of charge.



EVAWI's training bulletin, [Forensic Exams for the Sexual Assault Suspect](#), explores this topic in more detail and provides tools to help promote this recommendation for best practice.



Based on the obvious evidentiary value of suspect exams, why do you think they are underutilized in many law enforcement agencies across the country?

Not Just DNA Evidence

One common misconception about forensic exams is that their sole purpose is to collect DNA evidence. No doubt, advances in DNA technology and analysis, along with the development of local, state and national DNA databases such as CODIS,⁶ have had a profound impact on sexual assault investigations. However, besides DNA evidence, other types of evidence obtained and documented during these exams can also have considerable investigative value.

Nor is DNA evidence always the most *important* evidence for advancing a sexual assault investigation. In many cases, victims and suspects know each other, and suspects do not deny that the sexual act took place. Rather, most argue that the victim consented. A consent defense is therefore only overcome by evidence that corroborates the element of force, threat or fear – or establishes that the victim was incapacitated and could not consent to sexual acts. Typically, DNA evidence is not as useful for these purposes. This is more likely to be accomplished with good old-fashioned police work, such as interviewing victims, suspects, and witnesses, searching criminal justice databases, executing search warrants, canvassing residential neighborhoods for possible witnesses, checking for security cameras and digital evidence, etc.



Consider any sexual assault cases in your community that resulted in criminal prosecution. What impact did evidence collected during forensic examinations of the victim and/or suspect have? What specific evidence made a difference?

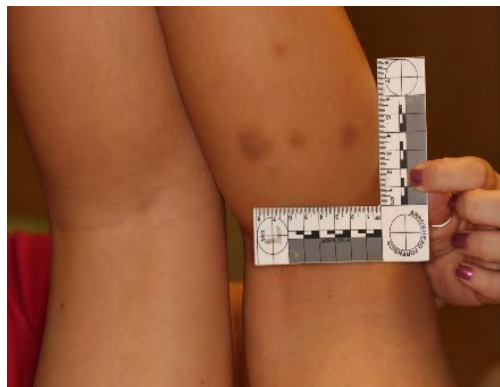Case Example

The case example below illustrates how the evidence from a victim's medical forensic examination can provide law enforcement investigators with additional "puzzle pieces," that expand what is known about the sexual assault and guide investigative strategies.

⁶ CODIS refers to the Combined DNA Index System, the national database of DNA profiles used for forensic purposes. It is hosted and governed by the Federal Bureau of Investigations (FBI).



🔍 A 19-year-old female named Tina (not her real name) presented at a hospital emergency department with a sexual assault complaint. She is an enlisted soldier stationed at a nearby military installation, and she was brought to the hospital by military police. Prior to the medical forensic examination, the police officer briefed the sexual assault forensic examiner (SAFE) on the known case facts: Tina was drinking with friends after work at a local bar/pool hall. She does not remember leaving the bar. She woke up with someone on top of her. She could not scream, but she wanted to. She passed out again, and then woke up in her bed, in the barracks, with her clothes off. She called her friend on the phone to tell her what happened, saying she is afraid she was sexually assaulted after she passed out. The next day, she also told her sergeant at work, because her friend encouraged her to get help.



During the exam, the SAFE: (1) obtained a medical forensic history from the patient (including questions about the assault), (2) completed a general physical assessment as well as an assessment of the genital region, (3) documented physical findings, and (4) collected forensic and toxicological samples.

After the exam, the SAFE informed the police officer that multiple injuries – both genital and nongenital – were present and documented. Also, a torn bra and bloody underwear (not from menses) were documented and collected. Overall, the assault history given was consistent with the police report (“I passed out”).

These findings from the victim’s exam offer new information about what may have occurred. Not only do the physical findings serve as possible indicators of sexual contact and the use of force, they also offer direction regarding what other evidence and statements investigators might seek. Any increase in information is critical at this point, given the relative absence of a victim history in this potential drug and/or alcohol-facilitated sexual assault.

Then if the suspect is identified within a few days (depending on case facts), an examination of this suspect could expand this information even further. For example, biological material from the victim could be located on the body or clothing of the suspect. Or the reference standard could exclude this person as a suspect in the case. Again, a forensic examination of the victim can have significant investigative value, but this can be increased exponentially with a suspect exam as well.



EVAWI’s OLT module, [Law and Investigative Strategy: What Kind of Sexual Assault is This?](#) discusses investigative strategies for sexual assault cases involving unconscious or incapacitated victims, including evidence collected and documented during the forensic examination of the victim and suspect.



Multidisciplinary Coordination for Examinations

Forensic Examiners

A standard recommendation for best practice is to have sexual assault forensic examiners (SAFEs) – health care providers who are specially trained to conduct sexual assault forensic examinations – collect and document forensic evidence from victims and suspects. Many jurisdictions utilize forensic examiners to perform victim examinations, but a growing number are using them for suspect examinations as well.

Sexual assault nurse examiner (SANE) programs began emerging in the United States in the 1970's, with specially educated nurses who were trained and clinically prepared to perform medical forensic examinations. These programs proliferated in the 1990s and, by 2018, there were over 900 such programs.⁷ Included in this number are SAFE and SANE programs that employ a broad range of trained health care providers, including: physicians, physician assistants, nurses, and/or nurse practitioners.

From a law enforcement perspective, it is a win-win situation for sexual assault victims to have access to specially trained and clinically prepared forensic examiners. They provide victims the medical care they need, while meticulously collecting evidence and documenting the assault history and exam findings. Ultimately, their efforts not only promote victims' healing from the sexual assault but also increase the chance that law enforcement will be able to move a case forward to prosecution, where the facts and evidence warrant (Littel, 2001). When investigators obtain the services of trained forensic examiners to conduct suspect examinations, this valuable investigative step can yield additional probative evidence.

The presence of medical forensic evidence significantly predicts sexual assault cases being prosecuted and ending in a guilty verdict.

Patterson & Campbell, 2012, p. 2261



As part of EVAWI's Expert Interview Series, Debra Holbrook provides a 3-minute response to questions such as: "[What is a forensic nurse? What is their role? How does a forensic nursing program work?](#)" Holbrook serves as the Treasurer for the Academy of Forensic Nursing and the Director of Forensic Nursing at Mercy Medical Center in Baltimore, Maryland.

Law Enforcement Involvement

Law enforcement should always be present during the forensic examination of a suspect, including being in the exam room when the physical evaluation is conducted.

⁷ Information provided by Kim Day, SANE-A, SANE-P, Forensic Nursing Director for the International Association of Forensic Nurses (IAFN), in a personal communication on June 23, 2018.



However, with victims, they may or may not be involved at the point of a medical forensic examination (we will discuss the reasons for this in Part II of the module).

When law enforcement is involved with a victim's medical forensic examination at this point, investigators should not typically be in the room for the physical examination. (There are some exceptions, however, for example when the victim is incarcerated). Yet law enforcement will almost always interact with victims before and after the exam (in response to a radio call, transporting the victim to the exam facility, interviewing the victim, completing the crime report, or providing the victim with information about the criminal justice process). It is also advised that they communicate with forensic examiners and crime scene technicians both before and after the exam, to maximize accuracy and identify evidence that needs to be collected and documented.



Many resources have been developed to improve responses of criminal justice professionals and others, based on an understanding of trauma and the impact of neurobiology on victim behaviors and memories. These materials include recommendations for how and when law enforcement interviews should be conducted, and how multidisciplinary professionals can work together to improve system responses to better meet the needs of traumatized survivors and their support people. One such resource is EVAWI's training bulletin, [Understanding the Neurobiology of Trauma and Implications for Victim Interviewing](#). We also offer several recorded webinars on this topic in our free [webinar archive](#).

VAWA Forensic Compliance

Sexual assault victims have a legal right to a medical forensic examination even if they have not yet decided whether to report their assault to law enforcement or participate in the criminal justice process. Certain provisions of the Violence Against Women Act (VAWA), often referred to as the *forensic compliance provisions*, ensure that victims of sexual assault do not have to speak with law enforcement professionals to have a medical forensic exam, and law enforcement authorization is not required for an examination to proceed. These provisions are meant to remove barriers to victim access to medical forensic care.

Specifically, VAWA mandates that victims of sexual assault must be provided with access to a medical forensic examination (1) free of charge (although this provision does not extend to all aspects of medical testing and treatment), and (2) without requiring them to cooperate with law enforcement or participate in the criminal justice process. In 2013, the reauthorization of VAWA further clarified that: (1) victims cannot be required to pay any out-of-pocket costs to obtain this examination, and (2) public outreach is required to ensure that community members know about this service.



For detailed information, see EVAWI's OLT module, [The Earthquake in Sexual Assault Response: Implementing VAWA Forensic Compliance Provisions](#).

Pre- and Post-Exam Consultation

There are many strategies that can help investigators obtain an accurate account of the sexual assault from victims and ensure that evidence collection and documentation are initially guided by that account. One is for investigators to meet with the forensic examiner, both *before* and *after* the victim's examination.

Before the Examination

Before the examination, consultation between the investigator and examiner can help establish the facts of the assault, as they are understood at that time. This information can then alert the forensic examiner regarding specific areas of the body that may include injury, as well as parts of the body and/or clothing that may contain evidence. Then while the examination is taking place, investigators can use this time to begin writing their reports.



Photo Credit: Shutterstock.com

Similarly, investigators will need to communicate with forensic examiners before a suspect examination is conducted, to share any relevant case facts that may help direct evidence collection and documentation.

Courtesy Room for Law Enforcement

One thing hospitals and other exam facilities can do to support law enforcement is to offer a room for investigators to begin writing their reports while a sexual assault victim is having a medical forensic exam. Many hospitals provide this space for officers investigating crimes involving medical treatment of the victim (e.g., assault with a deadly weapon, vehicular accident, elder and child abuse). Ideally, this room can have supplies of report forms and supplementals, any advisements to notify victims of their rights and available resources, and relevant sexual assault protocols, policies, and procedures. This is a simple measure and a welcome courtesy that can facilitate multidisciplinary coordination and improve sexual assault investigations and trauma-informed responses to victims.

After the Examination

It is also beneficial for law enforcement investigators to debrief with forensic examiners immediately after victim examinations, to compare notes of what was known about the assault prior to the examination and what was observed or learned during the examination. This consultation can also be used to identify whether there are any factual discrepancies

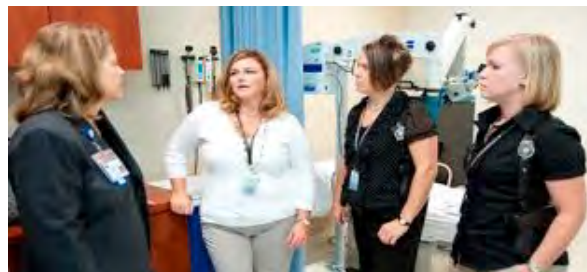

Photo Credit: St. Mary's Hospital, Forensic Examiners Program

in the documentation completed by the two professionals. For example, a victim may only tell an investigator about penile-vaginal penetration but then also tell the forensic examiner about oral copulation, anal penetration, or penetration with a foreign object. There are a number of reasons why victims might do this.

First, victims are often very concerned about their physical well-being, so they may be more inclined to disclose sensitive or embarrassing information about the sexual acts committed to a medical professional rather than an investigator. This is especially true if they feel safe and cared for by the forensic examiner, because this type of atmosphere can help victims disclose information that they may feel is particularly shameful or humiliating.

Also keep in mind that the investigator has typically conducted only a preliminary interview with the victim at this point. This is designed to gather general information about the sexual assault and evaluate the need for a medical forensic examination. The interview does not include all the detailed and systematic questions that a forensic examiner will ask as part of the exam process. Also, trauma, as well as possible drugs or alcohol, can affect the victim's ability to recall information during the preliminary interview with law enforcement; they may remember more details during the exam.

For all these reasons, it is important for law enforcement to consult with forensic examiners both before and after the forensic exam. This can help to ensure that the information documented by both professionals is accurate and consistent.

Clarify Discrepancies in Documentation

If there are discrepancies in the information provided by victims – or in the information documented by investigators and examiners – the investigator can gently ask the victim for help in clarifying the issue. Sometimes these are not really discrepancies at all, just a detail the victim told one professional but not the other. This could be because they were embarrassed about this information, or because they simply weren't asked about it. It could also be that the victim made a mistake, or one of the two professionals misheard, misinterpreted, or misunderstood what the victim was saying.



Responses Can Be Misinterpreted

In a webinar on [Trauma Informed Interviewing](#), Neva Fernandez of the Texas Legal Services Center provides examples of responses that a victim of physical or sexual violence might offer that could easily be misinterpreted if additional clarification is not sought by responding professionals. To illustrate, an investigator or forensic examiner might ask the victim, "Did he hit you?" and the victim might answer, "Not really." Or the professional might ask "Could you breathe?" and the victim might say, "Sort of." Responding professionals will do a great disservice to the victim and the case if they record the answers to these questions as "no" and "yes," respectively. Both answers should prompt the professional to ask for additional information to clarify what the victim actually experienced. Otherwise, the two professionals might record the victim's



responses differently and produce a discrepancy that is the result of one professional mishearing or misinterpreting the victim's response.

Inconsistencies or other issues can be clarified with the victim after this post-exam consultation, as long as it is approached in a compassionate and nonjudgmental way, to avoid alienating victims and jeopardizing the entire investigation. For example, if the question pertains to one or more of the sexual acts involved in the assault, the investigator can explain to victims that their embarrassment and hesitation to talk about the details of the assault is perfectly understandable. The investigator might even acknowledge how trauma can impact victims' memory recall.

Then the investigator can explain that a thorough investigation requires accurate documentation, so any questions must be resolved to the extent possible. This can be introduced by saying, "I need your help in sorting this out, because I have to write a report on this, and I want to get every detail correct." Investigators can also specifically ask victims whether the suspect committed sexual acts *other than those already described*. Just keep in mind that questions like this are more appropriate for a detailed follow-up interview, rather than a preliminary interview conducted during initial contact.



Is it standard practice in your jurisdiction to have a pre- and post-exam consultation with law enforcement and the forensic examiner? Can you think of a case where this would have helped identify additional evidence? Please explain.

Update Crime Scene Personnel

It can also be beneficial for investigators to consult with those processing the crime scene about case facts and exam findings that might help their evidence collection efforts. For example, they can be told if foreign fibers or debris are recovered on the bodies or clothing of victims or suspects, as this evidence might link them to the crime scene. Another example is that a victim might mention to the forensic examiner that a condom was used during the assault, that the suspect used a tissue or towel to clean his genitals afterward, or that a fingernail was broken during a struggle. Such information can be passed from forensic examiners to law enforcement, and then be provided to those processing the crime scene, to assist in searching for these items.



Can you think of a case where consultation between the investigator and crime scene technicians regarding exam findings or victim statements might have resulted in uncovering additional crime scene evidence? Please explain.

Implementation Guidance in Part II of Module

In Part I of this module, we provide some information about the multidisciplinary coordination needed to successfully implement victim and suspect forensic examinations. However, Part II will provide more detail on the policies and protocols



designed to translate this information into practice in a jurisdiction. Specifically, Part II addresses topics such as:

- Operational issues (exam location, timing considerations, payment, activation)
- Presence of others (professionals, victim advocates, other support people)
- Informed consent for victim exams (including capacity to consent)
- Pathways to victim examination based on point of first contact
- Victim exams conducted without law enforcement involvement
- Information that should be provided to victims about their rights, the forensic examination and the steps that will be taken in the investigation
- When the assault occurred in another jurisdiction
- Victim confidentiality issues and privacy needs
- Prior consensual sex and excluding DNA of consensual partners
- Multidisciplinary coordination and joint interviews
- Documentation and visual aids (alternate light sources, staining dyes)
- Collection, documentation, and packaging of evidence
- Special evidentiary considerations (clothing, hair samples, collecting toxicology samples and possible testing)
- Medical components of a victim exam (treatment for STI, HIV, pregnancy)
- Need for specialized training, strong supervision, and continuous improvement

We hope that professionals will supplement the foundational material provided in Part I of this module with the implementation guidance offered in Part II.

Managing Forensic Exam Records and Photographs

To standardize the collection and documentation of evidentiary samples during a forensic exam, jurisdictions often use tools such as exam protocols and evidence collection kits, instructions, and forms. While these tools are common for victim exams, a growing number of jurisdictions are also using similar resources for suspect exams.

Standardized Reporting Forms

A key tool is a standardized reporting form, which can be developed at the state level (as in California and North Dakota), or at the local level with input from forensic examiners and crime laboratory personnel. For victims, this reporting form typically includes completed consent forms related to evidence (not medical care) and documentation of the assault history. For both victims and suspects, the report also

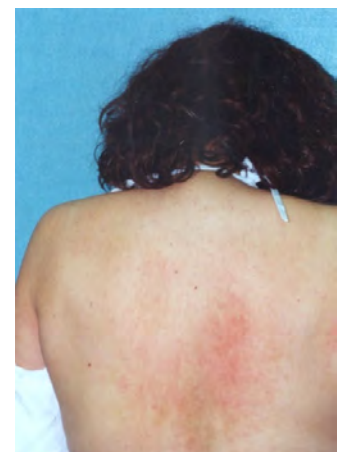includes documentation of any statements, observed behaviors, and demeanor that are potentially related to the assault, along with the physical findings and evidence samples collected. Documentation of medical issues will be limited to findings that potentially relate to the assault or preexisting medical factors that could impact the interpretation of any findings (adapted, *National Protocol*, p. 84). The completed report is usually submitted to law enforcement along with the evidence collection kit (if one is used).

These reports are extremely useful to investigators as they consider all the information and potential evidence that might be available and plan their next investigative steps. The exam reports can also provide forensic laboratory personnel with helpful information to assist in their analyses of evidentiary samples. The final report and the findings are also useful for prosecutors and juries, if a case advances that far. Yet this raises the question of who stores the exam report and photographs, who has access to these records, and whether they need to be provided in response to a subpoena.

Storage of Victim Records and Photographs

Given the privacy concerns associated with records and photographs from a victim exam, it is critical for multidisciplinary Sexual Assault Response and Resource Teams (SARRTs) to establish protocols that clearly outline the policies and practices regarding:

- Victim consent for the medical forensic examination and any associated photography;
- Agency responsibility for storage and maintenance of exam records and photographs; and
- Access, transfer, retention, and destruction.



These protocols must be developed with careful consideration and input from a variety of disciplines, including forensic examiners, law enforcement investigators, prosecutors, victim advocates, and attorneys specializing in victims' rights. They must also take into account the scenario where a victim has a medical forensic exam but has not yet decided to participate in the criminal justice process.

Some elements of the protocol should be non-negotiable. For example, photographs of intimate parts of the body (such as the genitals) should only be taken by medical professionals (National Protocol, p. 91). In rare circumstances, law enforcement may need to photograph non-genital injuries (e.g., breasts, chest, thighs). For example, a victim of sexual assault or intimate partner violence might have extensive physical injuries and be transported to an emergency room, but the facility might not have a trained forensic examiner or access to the best photography equipment. In that scenario, law enforcement might take the photographs, but everything possible should be done to respect the victim's privacy and modesty. For example, only an officer or crime scene technician of the same gender should take the photographs, and draping

should be used. It should go without saying that this should only take place with the victim's consent. Other protocol elements may be determined based on local policies, practices, and resources. It is important to review these protocols on a regular basis to ensure that they continue to meet current standards and best practices; improvements can then be made in an ongoing way, with multidisciplinary input from the SARRT.

Exam Records and Photographs in Medical Record

Throughout this module, we highlight many steps that can be taken by forensic examiners, investigators, and prosecutors to help protect a victim's privacy. One such recommendation is to use a standardized reporting form to document only the medical history related to the sexual assault, and then to store the report and photographs from the medical forensic examination separate from the victim's (patient's) medical record. This recommendation is clearly articulated in the National Protocol (p. 85):

The complete medical forensic record of the sexual assault visit should be maintained separately from the patient's medical record to limit disclosure of unrelated information and to preserve confidentiality. The medical record is stored at the exam site. The exam site should have clear policies about who is allowed access to these records.

Separating these records can be critical because a patient's medical records may include sensitive information that can be used to unjustly question a victim's credibility, (e.g., STI's, pregnancies, abortions, prescriptions, hepatitis, HIV status, depression).

To illustrate, exam documentation may be released in response to a subpoena or a signed release from the victim/patient, specifying which items are to be released (exam report, photographs, laboratory results, etc.) and to whom (law enforcement, prosecutors, etc.).⁸ When this exam documentation is released, this should not include other aspects of the patient's medical record, in the interests of victim privacy. In fact, these other aspects of the patient's medical record (other than exam documentation) should not be sought by investigators or prosecutors unless they are directly relevant to the investigation/prosecution, and the victim/patient consents to their release.



Digital Storage of Photographs

Many forensic examiner programs store photographs on CD's or downloadable files that are encrypted. A password or PIN is needed to open the files, which helps protect who has access to the photographs.

In some places, it is required by local policy or protocol to store the exam report and photographs in a patient's medical record. Others have contracts with law enforcement agencies specifying that the original record is maintained by law enforcement; the

⁸ Law enforcement agencies typically have such consent forms available because they request medical records for many different types of investigations (e.g., crimes against persons). However, if needed, consent forms can also be obtained from the medical facility from which the records are being sought.

forensic examiner program will keep a copy, but they are not the keeper of record. Still others have no clear requirement, and the local practice may simply be a matter of logistics or “the way it’s always been done.” There is a great deal of variation in the practices followed by different jurisdictions, because state laws and agency policies vary; it is always important to keep in mind that there are legal requirements for medical records that extend far beyond any potential involvement with the criminal justice system. For hospital-based programs, these decisions will be made by the hospital’s risk management team. Regardless, all the members of the SARRT (including forensic examiners, law enforcement, prosecutors, and victim advocates must be familiar with the laws and local policies regarding the confidentiality of all patient records.

Release of Records to the Victim/Patient

Regardless of where they are stored, both the medical record and exam documentation should be provided to victims/patients if they request it. As part of the informational material victims/patients are provided at the time of the exam, instructions should be provided for how they can request these materials.

Exam Report and Nongenital Photographs Stored by Law Enforcement

Based on the concerns outlined above, we recommend that the exam report and *nongenital* photographs should be provided to law enforcement along with the other evidence. If physical copies of the photographs or CD’s are provided, these should be impounded in the property room like any other evidence. However, some forensic examiner programs now manage all digital photographs as downloadable files. These encrypted files can then be accessed by investigators and prosecutors following established procedures.

Patients may at some point wish to view or obtain applicable medical records and/or law enforcement reports. They should have access to such documentation, and exam site and jurisdictional procedures for accessing this data should be conveyed to patients.

National Protocol, p. 48

Nongenital photographs of injuries may be necessary for investigators seeking to obtain an arrest or search warrant, and prosecutors considering filing charges. If investigators need photographs of nongenital injuries to demonstrate force, and they do not have access to the photographs taken by a forensic examiner, they will most likely take their own photographs. Or they may be unable to obtain the arrest or search warrant, both of which would undermine the trauma-informed approach communities are striving to achieve by having specially trained health care providers take these photographs during the exam process. A standardized process is needed for law enforcement to have easy access to nongenital photographs of injuries, so investigators can respond quickly.

Genital Photographs Stored by Exam Facility

On the other hand, *genital* photographs are more sensitive in nature, and they typically need to be interpreted and explained by a trained forensic examiner. Therefore, we recommend that genital photographs are stored by the exam facility as part of the exam documentation and not the patient's medical record. That way, they can be provided in response to a subpoena without jeopardizing the patient's entire medical record. Policies should be crafted to allow reasonable access for investigators and prosecutors.

If investigators or prosecutors need documentation of genital injuries – to support a request for an arrest warrant, or charges filed – they can typically use the body maps or diagrams completed as part of the reporting form. These are often more useful, because they can be more easily interpreted by someone without extensive training and expertise. They can provide the information needed by investigators and prosecutors for pre-trial considerations and any hearings such as an arraignment or grand jury, without the need for forensic experts.

Protecting Victim Privacy

While some professionals raise concern with law enforcement storage of exam documentation, there are a number of measures that can be taken to protect victim privacy and prevent the automatic release of records and photographs associated with a medical forensic exam.

For example, law enforcement agencies can work to ensure that copies of private or intimate photographs (either genital or nongenital) are not attached to the original crime report, or any supplemental reports (such as the investigator's follow-up investigation, or crime scene reports). These materials are filed in the Records Division of the law enforcement agency, and if such photographs are included in the documentation, they could be unintentionally released when a copy of the crime report is provided in response to a request for a public record. This would be a devastating violation of the victim's privacy.

Prosecutors can also take other measures to limit the dissemination of photographic evidence. For example, they can store photographs in a separate envelope (not in the file), explicitly marked: "Confidential, not subject to release." Prosecutors can also argue that photographic evidence should only be available for viewing by any involved parties, rather than copying. Prosecutors can even obtain a court order to prevent defense attorneys from copying any photographs or releasing copies to the defendant, and also ordering the destruction of copies and limiting dissemination to defense experts only.⁹

⁹ Some of this information is drawn from a presentation entitled, *Who gets the photos? Utilizing Photographic Evidence and Protecting Victim's Privacy*, at EVAWI's *International Conference on Sexual Assault, Domestic Violence, and Systems Change* in Orlando, April 18-20, 2017. The presentation was given by several experts (listed in alphabetical order): Jane Anderson (AEquitas: The Prosecutors' Resource on Violence Against Women), Joanne Archambault (EVAWI), Kim Day (International Association of Forensic Nurses), Jessica Mindlin (Victim Rights Law Center), Kris Rose (Office for Victims of Crime, US Department of Justice), and Gael Strack (Alliance for Hope International).



Protecting Victim Privacy

Law enforcement and prosecutors may need to work with sexual assault advocacy organizations (including state coalitions), to make sure there are laws in place allowing them to withhold a sexual assault victim's personally identifying information from materials entered into the public record. They can also ask judges to seal any search warrants sought in sensitive cases involving child abuse, sexual assault, intimate partner violence, and strangulation.

Suspect Records and Photographs

Because the forensic examination of a suspect is conducted primarily, if not exclusively for forensic purposes (not medical), the question of storage for exam documentation is more straightforward. As evidence in an ongoing criminal investigation, the forensic examiner's report and associated photographs from a suspect examination will typically be maintained by law enforcement just like any other evidence. Access will therefore be governed by standard legal requirements and local policies/protocols.

However, if the suspect exam is conducted in a medical facility like a hospital, the exam report and photographs may be stored as part of the suspect's/patient's medical record. In this scenario, the multidisciplinary SARRT will need to discuss the issues and ensure that investigators and prosecutors are well-informed of the procedures for protecting the ongoing investigation and accessing these records and photographs. This is the type of policy question we will explore in more detail in Part II of this module.

Responding to a Subpoena

Forensic examiner programs often receive subpoenas to provide exam records and photographs; some even request access to a patient's entire medical record. A subpoena can come from a prosecutor, a defense attorney in a criminal case, or as a result of civil litigation. Yet these records should not simply be handed over automatically in response to a subpoena. There are a number of steps a forensic examiner program should take before determining whether and how to release any such records or photographs. First is to check with a supervisor and review the relevant protocol, if there is one. If not, consult with legal counsel, whether the city attorney, county counsel, the hospital legal advisor, or even an attorney with the local sexual assault advocacy program or the state sexual assault coalition. All of this must be done promptly, because there are timelines to be considered and possible legal sanctions.

One key question is whether there is an active law enforcement investigation or criminal prosecution pending. This can be determined by calling the investigator, Department or Unit assigned to the case, advising of the subpoena and asking about the current status of the investigation. If the investigation is ongoing, the law enforcement agency can often protect these records by arguing that they should not be released while a criminal investigation is underway. This is another reason why we argue for storing the exam



report and photographs separate from the patient's medical record. Investigators may need to consult with their agency's legal advisers as well, to determine how best to protect the privacy of the victim and the confidentiality of the exam documentation as well as the integrity of the investigation.

If criminal charges have already been filed by the prosecutor's office, all requests for information or records should be handled by that office. Forensic examiners should contact the prosecutor's office to determine how to respond to any subpoena they receive for exam records and photographs. If there is no active investigation or criminal charges pending, forensic examiners should consult with their own legal counsel.



Protecting Records with a Subpoena Duces Tecum

Although an attorney may subpoena a victim/patient's entire medical record, this does not mean it must automatically be turned over. Given the sensitivity of this material, trained attorneys can file motions in court to restrict, limit, and/or prevent the disclosure of certain records, to protect patient privacy and the confidentiality of sexual assault records.

One strategy a Sexual Assault Response and Resource Team (SARRT) can employ to protect these records is to require all civil and defense attorneys to file a *subpoena duces tecum* (rather than a standard subpoena), when they are requesting exam documentation such as the exam report or photographs. While a standard subpoena is a summons for an individual or agency to present in court or provide certain records, a subpoena duces tecum orders an individual to personally appear in court and bring relevant documents for review by a judge. The judge is then able to review the records (usually in an in-camera, or private, hearing) to decide if the records should be released, and if so, to what extent.

The procedure for requesting this more protective type of subpoena should be spelled out in the local protocol, the development of which will require consultation not only with SARRT members (including forensic examiners, law enforcement and prosecutors), but also the legal representative for the forensic examiner program as well as attorneys for City and County agencies.

Purposes and Types of Evidence

Now that we have outlined the goals of a forensic examination conducted with a sexual assault victim or suspect and introduced some key concepts for understanding the role in the investigative process, we provide more detailed information about the types of evidence that can be collected during these exams and what purposes they can serve.

Scope of Evidence

Broadly, evidence collected and documented during a sexual assault investigation can come from a variety of sources. This includes:

- Statements obtained by law enforcement from victims, suspects, and witnesses, including responding professionals (such as law enforcement, emergency medical services, forensic examiners, and other health care or social service providers).
- Evidentiary samples and items that are collected and documented at the crime scene or other locations (like the victim's or suspect's home or apartment, car, or other personal items).
- Evidentiary samples and items collected during the forensic examination of a victim or suspect (from their bodies and clothing).
- Physical findings and documentation from victim and suspect examinations, including photographs and body maps or diagrams.
- Victim statements documented by a health care provider during the medical forensic examination, as well as observed behaviors and general demeanor.
- Suspect statements, behaviors, and demeanor documented during a forensic examination.

The probative value of each type of evidence can only be understood in the context of the entire investigation, with all the information and evidence that is available.

Physical Findings

When it comes to evidence specifically collected and documented during a forensic examination, *physical findings* from a victim or suspect include:

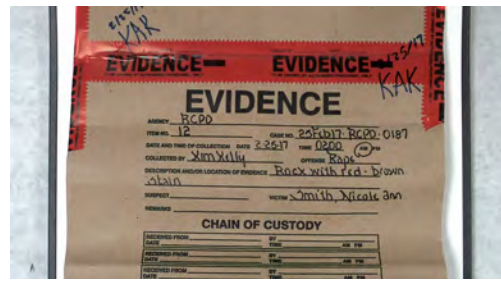
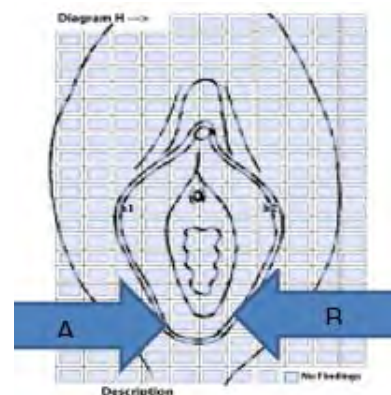


Photo Credit: Ted McDonald and Lauren Ware



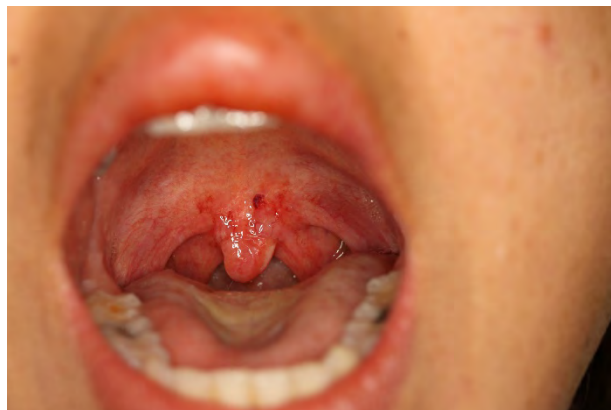Photo Credit: Ted McDonald and Lauren Ware



Any stains or substances detected;

- Any debris or foreign material detected;
- Injury detected or no injuries (normal physical finding); and
- Any subjective tenderness or pain described by the victim.¹⁰

Physical findings also include suspect characteristics that may help to identify the suspect or corroborate descriptions provided by the victim or witnesses (including general appearance, behaviors, demeanor, location of tattoos, piercings, etc.).



Multiple linear bruises on soft back palate above the uvula sulcus that could be the result of oral copulation or penetration with a foreign object.

Any physical findings are documented in a written report by the forensic examiner, along with photographs and body diagrams or maps (consistent with local policy).

Evidentiary Samples

Evidentiary samples from the forensic examination of a sexual assault victim or suspect generally fall in two categories: biological and nonbiological.

Biological samples may be found on skin, clothing, or other items such as condoms. These samples could have come from victims, suspects, or the crime scene. Biological samples might include hair, tissue, bones, teeth, blood, semen, saliva, or other bodily fluids.¹¹



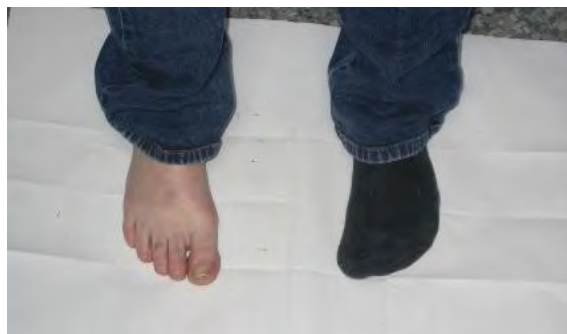In addition to the forensic exam of a victim or suspect, biological evidence can also be collected and documented at the crime scene or other location – for instance, on a towel or tissue used to clean up after the assault, on a discarded condom or condom wrapper, or on other items related to the assault. There may also be items at the crime scene on which biological material could have been deposited, such as bedding, upholstery,

¹⁰ Tenderness is defined as painfulness to pressure of contact. Due to its subjective nature, this can only be documented by the forensic examiner based on the victim's statements and observations of the victim's behavior and demeanor. Sexual assault victims, like everyone, have different tolerance levels for pain or touch as elicited by examination. Of course, tolerance levels can also potentially be influenced by drug and alcohol use, among other factors.

¹¹ Depending on the source of any biological evidence (clothing, bedding, towel, etc.), a DNA profile that is developed from it could belong to the victim or suspect, but it could also belong to a roommate, intimate partner, friend, family member, etc. This is why reference standards (typically buccal swabs) are needed to exclude any such individuals who are unrelated to the crime but potential sources of the biological material.

carpet, flooring, or other surfaces. Biological material might additionally be found on bottles, glasses, belts, or other objects used during the assault.

Nonbiological or trace evidence might also be collected and documented during a forensic exam; this can potentially associate victims, suspects, or crime scenes. Trace evidence is typically defined as including items and substances such as lubricants, contraceptives, debris, fibers, soil, sand, paint, or other foreign material. For example, soil from the crime scene may be detected on the clothing of the victim and the suspect, which could potentially associate the two as well as confirm the location of the assault.¹²



Whether biological or nonbiological (trace), any evidence that is visually detected during a forensic examination is collected following standardized procedures, after its location and appearance have been carefully documented. If the sexual assault is reported to law enforcement, both the evidentiary samples and items will be turned over, along with the examiner's report. If the victim has not yet made a decision regarding criminal justice participation, the protocol for handling the report and evidence will vary.



EVAWI offers an OLT module on [Crime Scene Processing and Recovery of Physical Evidence from Sexual Assault Scenes](#). It provides guidance on crime scene processing – a systematic, meticulous, and scientific process that law enforcement professionals should employ in every major criminal investigation.

Investigative Purposes

All evidence gathered during a sexual assault investigation – biological or nonbiological (trace) - can potentially be used to support one or more primary investigative purposes.

Purposes for Forensic Evidence in Sexual Assault Investigations

- Identify or exclude suspects
- Establish recent sexual contact
- Corroborate force, threat, fear, or incapacitation
- Corroborate statements (victim, suspect, or witnesses)

We will discuss each purpose individually, but keep in mind that evidence often meets more than one purpose, depending on the facts of the case.

¹² While hair is technically a biological sample that can be analyzed for DNA under certain conditions (if it contains the root, or with mitochondrial DNA analysis), it has traditionally been used as trace evidence and only analyzed for its physical properties and appearance.

Identify or Exclude Suspects

One primary purpose of forensic evidence is to identify or exclude suspects in a criminal investigation. This can be accomplished with DNA evidence, as well as latent prints or trace evidence. However, trace evidence does not provide anywhere near the scientific certainty offered by DNA or latent prints. In fact, it is rare to have a sexual assault case rest on trace evidence alone, especially given the frequency with which DNA evidence can be obtained and the expectation of juries that DNA evidence will be presented.¹³

Understanding DNA

DNA profiles can be developed from evidence collected from: the body or clothing of the victim; the body or clothing of the suspect(s); or items collected from the crime scene(s). These DNA profiles are referred to as *forensic unknowns*, but this does not necessarily mean the suspect in the case is truly unknown. Law enforcement may know who their suspect is, based on information provided by the victim or other sources. The terminology is simply used to distinguish a DNA profile developed from forensic evidence rather than reference standards collected directly from a known individual. Due to advances in DNA technology, increasingly smaller amounts of cellular material can yield usable amounts of genetic information. This is often referred to as “touch” DNA testing, and it is important to remember because DNA evidence can be very robust over time. For example, DNA profiles can sometimes be recovered from articles of clothing (such as the armpit of a shirt or sweater, the waistband of a pair of pants, the inside surface of a baseball cap, and the crotch area of an undergarments). Ropes, cords, and other restraints used to limit a victim’s movement might also yield DNA.



DNA Evidence is Robust

Remember, DNA may be recovered from clothing or crime scenes many weeks, years, and even decades following a sexual assault. Consider, for instance:

- The dress that the victim was wearing on the night of the sexual assault that is still hanging in her closet six months later, without having been washed;
- A cushion on the sofa where the sexual assault was committed; or
- The foreign object that was used during the assault.

¹³ Because of the astonishing technological advances and ever-increasing media attention on DNA evidence, some investigators forget to consider the value of collecting and documenting latent prints. This is a mistake, because latent prints are frequently available, and they can also be used to identify or exclude a suspect, or to corroborate victim or suspect statements. Prints can even help to establish the element of force or fear based on their exact location (e.g., on a weapon), and they can help to overcome a consent defense, for example, if the suspect states that the victim invited the suspect into the home, but latent prints are found on an outside window frame at a suspected point of entry.





For more information on DNA evidence and sexual assault investigations, please see two of EVAWI's OLTi modules: (1) [Crime Scene Processing and Recovery of Physical Evidence from Sexual Assault Scenes](#) and (2) [Laboratory Analysis of Biological Evidence and the Role of DNA in Sexual Assault Investigations](#).

Identifying or Excluding an Unknown Suspect

In some sexual assault cases, there is no definitive suspect. This can occur when the perpetrator is a stranger to the victim or due to the nature of the assault (it was dark, the victim could not see the suspect's face, the victim was incapacitated or unconscious, etc.). If a foreign DNA profile can be developed from evidence in the case (from the crime scene, or the victim's examination), this profile can often be submitted to CODIS in the hopes of identifying the suspect. If not, the investigator will begin with standard investigative techniques to gather information and identify possible suspects.

Once a suspect is identified, it is best to legally obtain DNA reference standards as soon as possible, either with the suspect's consent or other means (a search warrant). This reference standard should then be submitted for analysis as soon as practically possible, to confirm whether the biological evidence collected in the case was in fact contributed by the identified suspect, and a CODIS search for other matches can occur.

Of course, DNA can also exclude a suspect from consideration, if it is determined the individual is not the source of any biological evidence recovered in the case. Because it is based on DNA analysis, this can be achieved with a great deal of scientific certainty.

When the Suspect is Known

Even when the suspect is initially identified by the victim, any foreign DNA profile developed on the basis of evidence should still be submitted to CODIS. This is because a CODIS hit could advance the investigation in a variety of ways beyond suspect identification. For example, it could reveal that the suspect was arrested or convicted for a prior offense, or it could connect the suspect with additional crimes where a forensic unknown DNA profile was identified but a suspect, or the donor of the DNA, had not yet been identified.



DNA Testing Reveals Serial Perpetration

DNA is helping to reveal the extent of serial offending among sexual assault perpetrators. In Detroit, for example, a sample of 7,287 previously untested sexual assault evidence kits were submitted for analysis. As a result, 508 suspects were linked with more than one sexual assault case. Most of these (70%) were linked with two cases, but almost a third (30%) had DNA evidence linking them to more than two reported sexual assaults (Campbell et al., 2018).



In a similar effort in Cleveland, almost 5,000 evidence kits were tested between 2010 and 2016. As many as a fourth of reported rapes were committed by a serial perpetrator (Lovell et al., 2018).

Document Evidence of Recent Sexual Contact

A second purpose of evidence is to establish that recent sexual contact took place. During a medical forensic examination, all bodily orifices that the victim indicates were involved in the assault are therefore examined for bruises, tears, redness, or other signs of physical trauma to corroborate that sexual contact occurred. Swabs are used to collect DNA or biological samples of bodily fluid from locations where the victim indicates that the suspect's mouth or genitalia came into contact with the victim's body. The victim's body is also assessed for nongenital and genital trauma, as well as trace evidence (such as pubic hair), and findings are carefully documented.

Similar evidence collection and injury documentation occur during the suspect exam. For example, the examiner looks for biological material (such as vaginal secretions), trace evidence, and injuries (such as bruises or abrasions on the suspect's genitalia).

Evidence of Specific Type of Sexual Contact

Exam evidence from victims and suspects can sometimes help establish that specific types of sexual contact took place. For example, a suspect's semen might be found in a victim's vaginal area, establishing penile-vaginal penetration. A victim's epithelial cells might also be found on the suspect's fingers, corroborating digital penetration. (Epithelial cells line soft tissue surfaces, such as the vagina and mouth).

Evidence of Sexual Contact in General

Even if the evidence does not establish that a specific sexual act took place, it may indicate that sexual contact occurred more generally. For example, the suspect's semen or saliva may be recovered from the victim's skin in a nongenital area (stomach, back, arm, leg, face, etc.). Or the victim's epithelial cells might be found on the suspect's clothing. Associated trace evidence might also be recovered at the crime scene.

No DNA Evidence Doesn't Equal No Sexual Contact

It is worth noting, however, that victims and professionals often place too much importance on finding DNA evidence to establish that sexual contact occurred. While biological evidence can be used in some cases to establish that a specific sexual act was committed, the absence of such evidence does not prove it did not occur. In other words, a sexual assault investigation is not "doomed" if semen is not found. Sexual acts may be corroborated with other types of evidence, as we will describe in a moment.



Identification of Foreign DNA Profile

In one study, researchers analyzed data from 1,000 sexual assault cases where evidence was submitted to a crime laboratory. A foreign DNA profile was obtained from the victims' evidence collection kits about one third of the time (32%) (Gingras et al., 2009).

Document Evidence of Force, Threat, Fear, or Incapacitation

A third purpose of evidence is to document the force, threat, or fear used by the suspect to commit a sexual assault – or to document that the victim was incapacitated to the point where she/he could not consent to sexual activity.

Evidence of Force, Threat or Fear

Examples of evidence that may establish force, threat, or fear can include:

- The victim's account of the incident – not only what happened, but also what they were thinking and feeling at the time;
- Statements made by the suspect(s), and any witnesses, about what took place, particularly noting where they converge and diverge from the victim's account;
- Written documentation of genital and nongenital injuries on victims and suspects;
- Photographs, body maps/diagrams, and other documentation of physical findings from victims and suspects; and
- Torn, soiled, stretched or otherwise damaged victim or suspect clothing.

Typically, the presence of force, threat, or fear cannot be established with a single piece of evidence, but rather by describing all the circumstances of the sexual assault. Any time victims describe significant force during an assault, or when victims state that they bit, kicked, or scratched the suspect, related injuries on both victims and suspects might be identified and documented for days afterward. If there is damage to the clothing of suspects and/or victims, the damage can also be documented, and clothing collected.

Evidence of Victim Incapacitation

Examples of evidence that may establish the victim's level of incapacitation can include:

- Results of toxicological analysis of blood or urine samples from the victim;
- The victim's account of events before, during, and after the sexual assault, including what they were thinking and feeling, if they are able to recall;



- Statements made by the suspect(s), and any witnesses, about what took place, including the victim's behavior and appearance, as well as the suspect's role, if any, in the purchase, provision, or covert administration of drugs or alcohol;
- Digital evidence, such as pictures/videos capturing the victim's state and the suspect's behavior, before, during or after the assault, as well as text messages between the parties, voicemail messages, phone recordings, etc.; and
- Bar or restaurant tabs, or surveillance videos taken from cameras located inside or outside the bar or restaurant where critical events took place.

Of particular interest in this scenario is the question of when and how the victim got home. In many cases, the "good Samaritan" who offers to help the victim get home safely is actually the one who takes advantage of the victim's vulnerable state and commits a sexual assault. Again, this can be investigated through statements made by the victim, suspect(s), and other witnesses (including roommates, neighbors, etc.), and other forms of evidence (such as surveillance videos, cell phone pictures, etc.).




In Atlanta, police investigated a sexual assault based on a Facebook Live video broadcast from a popular nightclub. As reported by [11 Alive](#) (a local NBC affiliate), the woman in the video appeared to be incapacitated by drugs and/or alcohol, and she is heard screaming and pleading "Help me," "Stop." Such video evidence captured on cell phones or security cameras, as well as digital photographs, can be crucial in a sexual assault investigation, particularly when the victim is unable to recall events or provide an account of what happened.

Corroborate Statements of Victims, Suspects, and Witnesses

A fourth purpose is to corroborate, or challenge statements made by victims, suspects, and witnesses. In fact, any evidence collected and documented during a forensic examination can potentially be used for this purpose. For example:

- Suspect exam documentation could corroborate information that the victim provides about sensory experiences during the assault, such as the suspect's smell (cigarettes, body odor, aftershave, bad breath, etc.), particularly if the examination occurs soon after the reported assault.
- Trace evidence such as leaf debris could be found on the suspect's or victim's body that resembles leaves found on the bushes outside the victim's home and the suspected point of entry. Another example is a suspect who is employed as a painter; paint chips might be found on the suspect's clothing, as well as the couch where the victim indicated the assault occurred.



- If the victim says the suspect used a condom, lubricant, or other object during the sexual assault, the recovery and analysis of those objects, or residue, could corroborate the victim's statement. For example, a condom wrapper may be recovered from the crime scene that matches a specific brand of condoms belonging to the suspect – or the residue from that brand of condoms might be found at the crime scene (e.g., spermicide or lubricant). The same evidence could also link the suspect to the victim (for example, if the same residue was identified on the suspect's and victim's body or clothing). It could also corroborate the facts of the sexual assault. Of course, these objects may also help to identify the suspect, if they have biological evidence on them, such as the suspect's seminal fluid or blood – or saliva or epithelial cells if the suspect tore the wrapper open with his teeth. DNA testing has become increasingly sensitive for biological material recovered in minute amounts (often referred to as "touch" DNA).



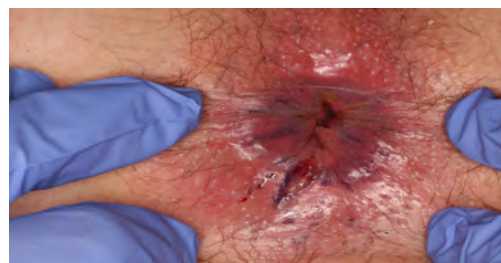These examples illustrate the importance of collecting evidence from the crime scene, even if it is not yet clear whether it will prove to be probative. Even if the evidence does not appear to establish a specific element of a sexual assault offense, any aspect of the victim's or suspect's that is corroborated can potentially advance the investigation. At the same time, evidence can refute, or challenge statements made by the victim, suspect, or witnesses. Either way, this evidence is critical for fact finders to determine what took place.

The Benefit of Corroborating Evidence

DNA evidence is more likely to be crucial as corroborative evidence when suspects deny committing a sexual act. In most cases, however, suspects acknowledge that the sexual act took place, but state that the victim consented. Or suspects begin by denying that the sexual act took place but switch to a defense based on consent once they are confronted with evidence such as DNA. In these cases, DNA evidence can be used to corroborate, or call into question, statements made by one or both parties.

For example, when the victim and suspect provide different accounts of the specific acts committed, biological evidence may help lend credibility to one version or the other. Perhaps the suspect admits to certain acts reported by the victim, such as oral contact with a victim's breasts, or penile penetration of the victim's vagina, but states that the acts were consensual. However, the suspect may deny other acts reported by the victim that may be seen as less socially acceptable like sodomy (penile-anal penetration) or penetration with a foreign object. Then if the suspect's semen is found on the victim's rectal swabs, this would corroborate the victim's account and challenge the suspect's account. Therefore it is critical for investigators and examiners to obtain a detailed account of the sexual acts from victims and suspects (if a suspect agrees to an interview) and focus particular attention on evidence documenting where their statements diverge.

Biological evidence and documentation of physical findings can also corroborate the element of force. For example, if a victim presents with lacerations or abrasions around the anus, and semen is detected on rectal swabs, these findings can help support the conclusion that the injury was caused by penetration with a penis. The evidence does not, however, conclusively establish whether the contact was consensual. Ultimately, evidence to establish force, threat, or fear is what challenges a consent defense. Nonbiological evidence, such as damaged victim or suspect clothing, may also help to corroborate the element of force, as well as statements made by the victim, suspect(s), or any other witnesses (including responding professionals like forensic examiners, investigators, and others).



Anal lacerations from 5-7 o'clock. Laceration at 7 o'clock oozing serosanguinous blood. Positive blue dye uptake.



Suspect Exams and the Consent Defense

Unfortunately, many investigators assume that a suspect examination will not be useful if establishing the suspect's identity is not critical to a case. That assumption may not be true. A suspect examination may still be useful in a case with a consent defense, because the evidence may corroborate the victim's and/or the suspect's account of events. The evidence may also document force or injury, which is critical for addressing a consent defense.



Case Example

The following case illustrates the power of physical evidence to corroborate statements made by the victim, suspects, and any witnesses in cases with multiple perpetrators.



In a case from the San Diego Police Department, a high school girl with a developmental disability was sexually assaulted by several teenage boys, who wanted to force her into prostitution. Five to six boys were originally thought to be involved in the incident. Following the assault, the girl disclosed to her parents, and the police were called. The victim had a medical forensic examination and her clothing was collected as evidence. During her initial interview, the victim identified two of the boys involved in the assault, and they were immediately arrested. The suspects were examined by a sexual assault forensic examiner (SAFE) and forensic evidence kits were collected.

Given the multiple suspects believed to be involved in the assault, all available evidence was analyzed by the crime laboratory, including the victim's forensic

evidence kit, her underwear, pants, shirt, and sweater, and the two forensic evidence kits collected from the suspects. Results indicated the following:

- *Semen was found on the victim's shirt, vaginal swabs, oral swabs, and anal swabs.*
- *Saliva was detected on both the right and left breast swabs.*
- *Semen and epithelial cells were found on penile/scrotal swabs from the two identified suspects.*
- *At least three contributors of semen were detected on the victim's vaginal and anal swabs, corroborating her statement of being raped by multiple perpetrators.*
- *However, the oral swabs had a single semen source that did not match either of the two identified suspects, nor did it match the three sources found on the vaginal and anal swabs. Continued investigation revealed the identity of several more suspects, and DNA testing of their reference standards linked one of them to the semen found on the oral swab.*
- *DNA testing of the suspects' penile/scrotal swabs also produced sperm fractions that were a mixture of more than one individual, not including their own. These findings indicated that each of these two suspects had semen on their penile/scrotal swab that originated from other males. These findings provided further corroboration of the gang rape scenario, explaining why one suspect would have DNA from one or more other suspects on swabs collected from his penis/scrotum.*
- *In addition, analysis of the non-sperm fraction of each suspect's penile/scrotal swabs produced a DNA profile consistent with the victim, indicating that the victim's vaginal epithelial cells were present.*
- *Finally, the left and right breast swabs taken from the victim produced a single male profile that matched a fourth suspect later identified in the investigation.*

Without the evidence from both victim *and* suspect forensic examinations, it would have been difficult, if not impossible, to corroborate the sexual acts in this complex scenario.

Initial Focus on the Victim's Account

To determine whether evidence collected and documented during a forensic examination meets one or more of these primary purposes, investigators must evaluate its potential value within the context of the victim's account of what happened. This is because the medical forensic exam is typically one of the first steps taken during the investigation; it is often done when the only other evidence in the case is the victim's initial statement. The victim's account is therefore the starting point for the investigation.

- To illustrate, victims may tell a first responding officer that the suspect licked or kissed their body in certain locations. This information is critical for the forensic examiner to know, so those areas can be swabbed. Then, if the suspect's saliva is found in these locations (as a result of laboratory analysis of the swabs), the evidence can corroborate the victim's description of what happened (or not).
- DNA found on the swab also establishes recent sexual contact between the suspect and the victim, although it cannot establish whether or not the act was consensual. DNA from saliva, located on specific parts of the victim's body (such as the victim's vulva or anus), can additionally establish the elements of the crime of oral copulation as defined in the state's penal code.
- The DNA profile developed from the swab will also be entered into CODIS in the hopes of identifying (or excluding) a suspect, as well as possibly connecting the suspect to additional crimes.
- The same considerations apply to swabbing those areas of the suspect's body where, for example, a victim reports being forced to orally copulate the suspect's penis, or the suspect penetrated the victim's anus with a finger. In this scenario, the victim's DNA could potentially be recovered from the suspect's penis, scrotum, or fingers. Any injuries documented on the suspect's body might also corroborate the victim's statement of forceful physical resistance and this should be carefully documented and photographed by the forensic examiner.

Again, the history of the assault provided by the victim is corroborative evidence, and it guides the evidence collection and documentation that will advance the investigation.



For more information about victim statements in a sexual assault investigation, please see the following resources:

- EVAWI's OLT module, [Interviewing the Victim](#), addresses in detail the fact that victim statements are crucial to any investigation, if approached with the right interviewing techniques as well as competence and compassion. Of course, the opposite is also true. Mistakes made during victim interviews can have a disastrous effect on victims' perceived credibility and cooperation. One mistake is treating victims like evidence, but another is treating them like suspects. This issue is addressed in a Training Bulletin entitled, [Interviews with Victims vs. Suspects: Start by Believing and the Question of Bias](#).
- The OLT module [Interviewing the Victim](#) also discusses challenges that result when victim statements are incomplete, inconsistent, or untrue. As previously noted, this is often due to the documentation by professionals, including law enforcement investigators who do not tape their interviews; taping is recommended to preserve the victim's statement exactly as it was relayed. Also see: [Incomplete, Inconsistent, and Untrue Statements Made by Victims: Understanding the Causes and Overcoming the Challenges](#).



- Understanding the common experiences of sexual assault victims can help investigators recognize the importance of documenting these experiences for investigative purposes. One resource on this topic is EVAWI's OLT module, [Victim Impact: How Victims Are Affected by Sexual Assault](#).
- The victim's actions before, during, and after the assault should also be documented in the investigator's follow-up report. Strategies are described in several of EVAWI's OLT modules, including *Interviewing the Victim* and [Effective Report Writing: Using the Language of Non-Consensual Sex](#).

Types of Evidentiary Samples and Items

There are a variety of evidentiary samples and items documented and collected during forensic examinations of victims and suspects. This section focuses on their potential probative value in sexual assault investigations. For each evidence type, **investigative purposes appear in bold**, to make it clear that the same type of evidence might serve different purposes, depending on case facts. Appendix A, *Purposes of Common Evidentiary Samples*, then summarizes this information as a reference tool.

Documented Statements, Behaviors, and Demeanor

As part of the exam process, forensic examiners document the victim's account of the sexual assault, along with other statements, behaviors, and general demeanor.

During the suspect examination, both forensic examiners and investigators (who should be present during any suspect exam) also document any spontaneous statements, behaviors, and demeanor made by the suspect. However, forensic examiners will seek only limited information from suspects about their medical history or hygiene, to help understand and interpret physical findings. This is because their role is not to gather an account of the incident from the suspect.

In fact, when suspects invoke their right to remain silent, the examiner should not typically ask any questions at all, because the examiner is acting under the legal authority of law enforcement (either with suspect consent, incident to an arrest, or to execute a search warrant). If a question is asked, the suspect can certainly refuse to answer. Even if the suspect does answer after invoking the right to remain silent, the statements obtained will be inadmissible in court. When suspects waive their right to remain silent, however, the forensic examiner can go ahead and ask questions relevant to the assault or a medical history.

Investigative Purpose

Documentation of statements, behaviors, and demeanor during a forensic exam primarily serves to **corroborate case facts**. For example:

- Victim statements to the examiner beyond the medical history may name the suspect, describe sexual acts, and/or characterize the use of force or coercion during the sexual assault (such as “I was so scared, I just froze”). Victim descriptions of what happened might then be corroborated by evidence obtained.
- Spontaneous statements made by a suspect might deny the sexual acts or characterize the victim’s (non)consent, which may corroborate or conflict with physical evidence collected from the victim, suspect, and/or the crime scene.

Foreign Material on/in Body Surface and Orifices

The surface of the body, and oral, anal, and genital orifices offer potentially rich sources of biological and nonbiological (trace) evidence. Foreign material may be found on or in these areas on victims and suspects, depending upon the facts of the case.

Body Surface Swabs

During a forensic examination, swabs can be obtained from any “suspicious” area on the body surface, based on information provided by the victim or other witnesses (when victims are unable to provide an account of the assault because they are very young, severely disabled, or incapacitated by drugs or alcohol). Swabbing will also be guided by the forensic examiner’s visual assessment. This could include swabbing:

- Any dry or moist secretion or stain, which could be biological material (saliva, semen/seminal fluid, vaginal secretions, blood, or sweat) that the forensic laboratory could analyze for DNA;¹⁴
- Any area that fluoresces with longwave ultraviolet light;¹⁵ and
- Any area where victims indicate bodily fluid may have transferred due to licking, kissing, biting, sucking, dripping, etc.




Photo Credit: Debra Holbrook

If the assault history is absent or incomplete, swabs are usually collected more broadly from “potentially high-yield” areas, such as the neck, breasts, or external genitalia of victims and suspects. Again, this may yield biological material as potential evidence. In

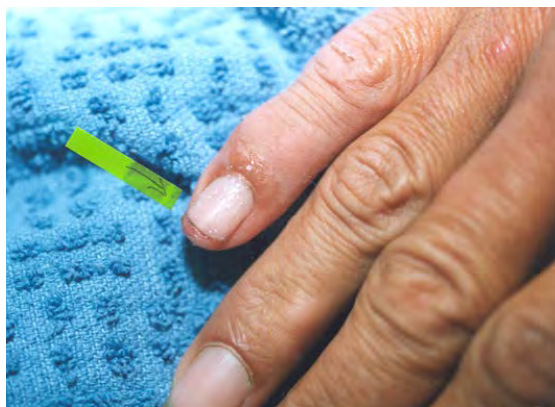¹⁴ Less common biological material found during a forensic examination includes urine, fecal material, and other bodily tissues and fluids such as mucus, ear wax, dandruff, and vomit. Despite the infrequency of their collection, it may be possible to develop a full or partial DNA profile from these materials.

¹⁵ Forensic examiners may use an alternate light source (fluorescent light) when scanning for evidence on the body and clothing, to help locate biological and trace materials that are otherwise not visible, or barely visible, to the naked eye.

addition, debris such as dirt, leaves, fibers, and hair may be found on the body, as well as materials like broken fingernails, particles from objects used in the assault, etc.

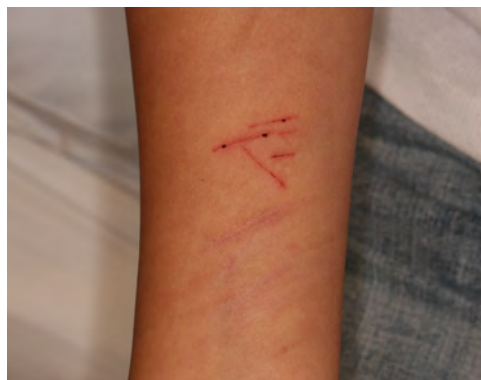Foreign material may also be recovered using fingernail clippings, scrapings, and swabbings of the fingers (including underneath the fingernails). For example:

- When a suspect has forced digital penetration of the victim's vagina or anus, it is common for epithelial cells from the victim to accumulate on the suspect's fingers, either under or near the fingernails. Evidence may be available even if the suspect bathed since the assault, as most people do not routinely scrub underneath their fingernails.
- It is also possible for biological material (such as skin cells or semen) to end up on the fingers or under the fingernails of a person who has orally copulated a penis, if they used their hand during the act.
- Fingernail scrapings or finger swabbings may be particularly important if there is evidence that the suspect or victim scratched the other party, or if the fingers of either person entered the other party's mouth, nose, or eyes.
- DNA from a person's sweat may even be recovered from fingernail scrapings or finger swabbings, if laboratory technology is sensitive enough.



Investigative Purposes

In addition to **identifying (or excluding) a suspect** and **establishing sexual contact**, evidence on the body surface may also be used to **corroborate case facts**. For example, victims may indicate that they scratched their assailant. Foreign material may then be recovered from under the victim's fingernails, and if a suspect is identified and located, a scratch found on the suspect's body can be documented and swabbed for DNA during the forensic examination. Foreign material under the victim's fingernails, the scratch on the suspect, and any DNA obtained from swabbing the scratch may all link the victim to the suspect.



Foreign material on the body surface of victims or suspects may also **corroborate the use of force** during the sexual assault, such as blood, broken fingernails, or dirt in a wound. For example, a victim may have one or more fingernails (either real or artificial) break off during the sexual assault. Pieces of the broken nails may also be found on the

suspect's body or clothing and/or the crime scene. In this situation, the broken fingernail can corroborate the element of force and the victim's account of the assault.

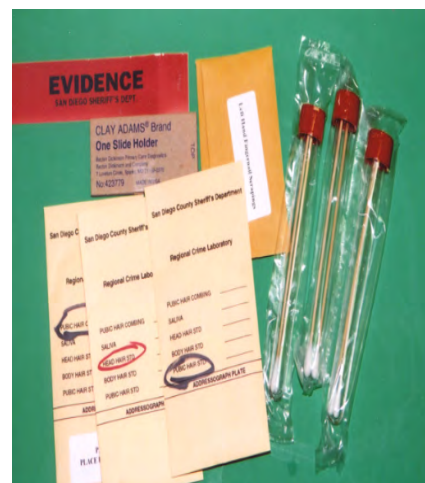
The location of biological material on the suspect's or victim's body may also prove important in **establishing the specific acts involved in the sexual assault** (penile-vaginal penetration, digital penetration, anal penetration, oral copulation, etc.). Alternatively, it may **indicate sexual contact more generally**. This can be particularly important in certain types of cases. For example:

- Documenting the location of foreign material such as DNA on the body may be particularly helpful in cases with victims who are very young, have a moderate to severe cognitive disability, are under the influence of drugs or alcohol, or are very disoriented by the trauma they experienced. This is because they may not be able to fully or even partially recall the assault or articulate exactly what happened to them and/or describe the sequence of events.¹⁶
- Documenting the location of foreign material on the body can also be important in cases involving multiple perpetrators (as illustrated in the case with multiple perpetrators from the San Diego Police Department), or in investigations where a victim is clear that they were sexually assaulted but is not sure if there was penetration. This can be especially true when the victim is young or sexually inexperienced.

Oral and Genital Orifices

Oral and genital swabs containing biological material are often the most probative evidence in sexual assault cases, depending on the account of the assault. Swabs can be sought from in and around body orifices of victims and suspects. For instance, oral swabs should be sought from the victim's mouth and lips in a case involving forced oral copulation of the suspect. Swabs from the victim's anus and rectum should be sought when a victim reports penetration by a suspect's penis, finger, or a foreign object.

Again, depending on the account of the sexual assault, and the specific acts described, these swabs are often the first evidentiary specimens to be analyzed for DNA evidence. Oral and genital swabs may recover biological material, such as semen, epithelial cells, vaginal secretions, blood, saliva or lubricant, that can provide probative evidence of the sexual assault offense on several fronts. For instance, evidence from a cervical-vaginal swab might recover semen that leads to **identifying (or excluding) a suspect, establishing**



¹⁶ For young victims and those with severe cognitive disabilities, it is recommended that interviews be conducted by forensic interviewing specialists. For more information and resources, please see our OLT module: [Successfully Investigating Sexual Assault Against Victims with Disabilities](#).

sexual contact, proving the elements of penile-vaginal rape, and corroborating case facts. Certain biological material – such as blood or pieces of a tooth – might also **indicate the use of force.**

To further explore the possible uses of biological evidence in a sexual assault investigation, it is important to break down the various types of evidentiary samples that might be recovered, including semen, saliva, blood, and hair.

Semen/Seminal Fluid

Semen is the most common source of DNA evidence in penile-vaginal rape cases. Semen may be left by a male suspect either in/on a victim's body, on the clothing of the victim or suspect, or on other objects and surfaces found at the crime scene.

Semen is composed of cellular and liquid components known as spermatozoa (sperm) and seminal fluid. Semen evidence is typically analyzed by crime laboratory personnel for spermatozoa and acid phosphatase (ACP). ACP is an array of related isoenzymes found in much greater concentration in semen than in any other body fluid. A high level of ACP at some locations on the victim's body would indicate that there had been recent sexual contact with seminal fluid.

Investigative Purposes

Depending on its location, semen can serve a variety of investigative purposes:

- The location of the semen can provide evidence to **establish recent sexual contact** with a male suspect. Semen found in samples taken from the victim's vagina, anus, or mouth would, for instance, provide evidence of sexual penetration in those bodily orifices. (Just keep in mind the limited timeframe for foreign material to remain recoverable in the mouth.) If the victim and suspect were both males, however, the semen may be from the victim. Laboratory analysis would need to make clear if the DNA profile is from the victim or another person.
- Even if semen is not located on the victim's body, it can still provide evidence of sexual contact, if it is recovered from the victim's or the suspect's clothing, or from an object associated with the sexual assault, such as bedding, condoms, or a foreign object.
- The location of the semen may also **corroborate the facts of the sexual assault**, if it is found in places where the victim describes sexual contact, or if it is found on the clothing of the victim or suspect or other objects associated with the sexual assault, consistent with the victim's account of events.




Photo Credit: Flickr

- Regardless of its location, laboratory analysis of semen can also be used to **identify (or exclude) a male suspect** with a high degree of scientific certainty.

Recovery of Semen Over Time

The likelihood of semen being recovered from the victim's body during a forensic examination depends on its location and the length of time since the sexual assault occurred. Yet DNA research and advanced testing technologies continue to extend time limits for the collection of biological evidence, including semen. To illustrate:

- A 2015 study by Speck and Ballantyne focused on DNA detection in the cervix and vaginal posterior fornix, after an extended time following penile-vaginal intercourse. The researchers were able to detect DNA more than 50% of the time *ten days after sexual intercourse* for menstruating women on hormone birth control and more than 65% of the time for women without menstruation or hormones.
- Semen has even been found in the vagina of a deceased victim up to 16 days after death. In a case investigated by the San Diego Police Department, semen was still present after this length of time because there had been no physical drainage due to the victim's posture at the time of death.



Not Just Semen

Too often an assessment of whether probative evidence may exist in a sexual assault case is based solely on whether semen was found. This myopic view can hinder an investigator's ability to advance sexual assault cases where no semen is detected. Also, it is critical to recognize the many reasons why semen may not be recovered even when penile penetration is reported. Consider the following scenarios, as detailed in the *National Protocol* (p. 97):

- The suspect may have used something other than his penis for penetration.
- The suspect may have used a condom, ejaculated somewhere other than the victim's body or clothing, or not ejaculated at all.
- The suspect may have had a vasectomy or depleted semen as a result of frequent ejaculation. If a suspect who had a vasectomy ejaculated, the seminal fluid would not contain sperm.
- Semen production may also have been suppressed due to chronic alcohol or drug abuse, chemotherapy, cancer, infection (like mumps or tuberculosis), or congenital abnormalities.
- Other factors may also contribute to the absence of detectable amounts of semen or seminal fluid. For instance, significant time delays between the



assault and collection of evidence may cause loss of semen evidence, semen may be washed away prior to the exam, or it may be improperly collected.

Saliva

Saliva is the second most common source of DNA evidence in sexual assault cases. It is common for suspects to kiss, lick, bite, or suck on victims' bodies during a sexual assault, yet the significance of saliva evidence is often overlooked. When victims say that the suspect licked, kissed, bit or sucked on any part of their bodies, those locations should be swabbed to collect saliva evidence.¹⁷ Likewise, when victims state that suspects forced them to lick, kiss, or suck on parts of their bodies, those areas should be swabbed during a suspect examination. Saliva can also be left on clothing and objects such as cigarette butts, cups, soda cans, and partially eaten food.

Investigative Purposes

Saliva evidence can often be used to **identify (or exclude) suspects** and **corroborate the facts of the sexual assault**, as described by victims, suspects, or witnesses.

- Saliva evidence may be particularly critical in cases where victims do not believe that the suspect ejaculated or where the suspect used a condom. In these instances, seminal fluid is unlikely to be obtained and saliva evidence can take on heightened importance.
- It is important for investigators and forensic examiners to ask victims whether the suspect's mouth touched them, and if so, where. However, victims may not remember everything the suspect did during the sexual assault, as a result of being unconscious, semi-conscious, incapacitated, or traumatized. It is therefore common practice to swab high-yield areas of victims' and suspects' bodies that are commonly involved with sexual activity (e.g., breasts, neck, vaginal area, penis). This is especially critical in cases where the history provided by a victim is unclear or incomplete. A DNA profile may result from such swabbing for saliva.

¹⁷ Saliva around bite marks is commonly collected as a possible DNA source. Dental impressions, clays, or overlays can sometimes be developed (Riviello, 2013), but with the availability of DNA evidence, dental patterns are rarely used in modern sexual assault investigations (Golden et al., 2015; Kaur et al., 2013; Lewis & Marroquin, 2015). However, bite marks found on the victim's body can serve as an indicator of force by the suspect, or on the suspect's body as a defensive wound from the victim's physical resistance (Riviello, 2013).

Blood Evidence

Blood recovered from the body or clothing of victims or suspects, or on objects from the crime scene, can help to **document the use of force** and **corroborate the facts of the sexual assault**. For example, if blood is recovered during the victim's forensic examination, it could be the result of injuries sustained by either the victim or suspect. Physical injuries are certainly consistent with the use of force during a sexual assault, and they can corroborate statements of the victim, suspect, or witnesses if their presence and location are consistent with the facts as described in these statements.



Photo Credit: Shutterstock.com

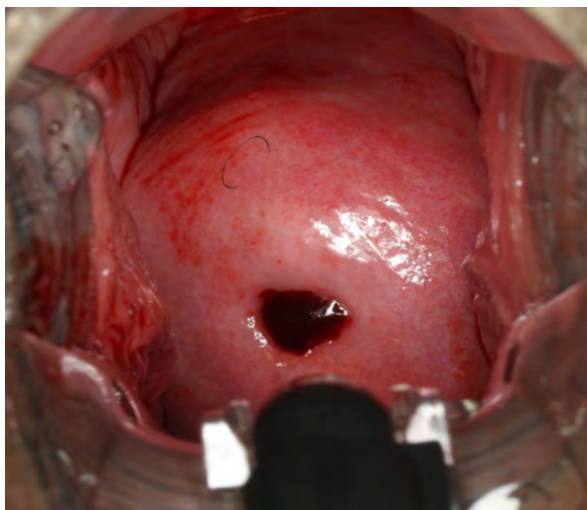


Injury vs. Menstruation

Note that while blood can be the result of injury, it could also be transferred from a menstruating female to a suspect. Sometimes, the injuries and assault history identified by investigators and forensic examiners can be enough to establish that the blood is a result of an injury. Similarly, a medical forensic examination of the female genital structures and a speculum exam can identify blood at the cervical os associated with menses.

However, depending on the circumstances of the case, investigators and

prosecutors might need a forensic laboratory to determine whether the blood is from an injury rather than menses.



Cervix with menstrual blood in os.

To differentiate between these two sources of blood, a sophisticated medical laboratory needs to test for a hormone or other marker, and this type of specialized analysis is not readily available in most crime laboratories. It may also be cost-prohibitive in many situations. However, it can be considered as a possibility for investigators and prosecutors when it is relevant given the facts of the case and the assault history.

Hair Evidence

Hair samples are routinely collected during the forensic examination of a victim or suspect. This includes hair found on the body surface or clothing, as well as hair combings, and clippings that could be used as reference standards. However, hairs are *not* typically used to identify or exclude a suspect, because they do not usually include the root, which is required for DNA analysis. The root is only present if the hair has been pulled or plucked.¹⁸ Foreign hairs recovered from the victim, suspect, or crime scene will typically be loose, so they cannot be analyzed for DNA to identify someone with scientific certainty.

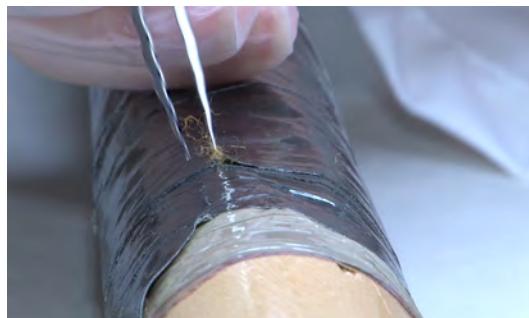

Photo Credit: Flickr

Hair may have investigative value as trace evidence, but research suggests it is rarely analyzed by forensic laboratories, and it generally has little to no impact on sexual assault investigation and prosecution (Peterson et al., 2010). One reason is because other types of biological evidence will typically be examined before hair, in the hopes of identifying a DNA profile. Trace evidence will generally only be examined in cases where DNA could not be identified, and it typically cannot produce an identifying match. Instead, laboratory reports on trace evidence will often state that the item in question “cannot be excluded from having a common origin as the known sample.”

On the other hand, hair evidence can be used to **corroborate the use of force**, if the victim reported that the suspect pulled out chunks of the victim’s hair during the assault. This is an under-utilized strategy. In most non-stranger sexual assault cases, and even many stranger sexual assault cases, the defense strategy will be to argue that the victim consented to the sexual acts. By corroborating the victim’s statement that the suspect pulled out a chunk of hair during the assault, this helps establish the element of force and challenge the suggestion that the sexual contact was consensual.¹⁹



During the forensic examination of a sexual assault victim and suspect, one question is whether to snip or pluck hair samples taken from the head and pubic area. Joanne Archambault (2000) answers this question in [an article published in *Sexual Assault Report*](#). The answer? Snip. The article explains why.

¹⁸ Unless hair has been forcibly pulled from a person’s body, it will not typically contain sufficient tissue at the root for nuclear DNA analysis. Mitochondrial DNA (mtDNA) analysis is still possible, but it is far less discriminating than nuclear DNA. Also, mtDNA profiles are not accepted into CODIS (in the Offender Index, Arrestee Index, or Forensic Index); they are only used to search for unidentified human remains, missing persons, and relatives of missing persons. For more information, please see the OLT module, [Laboratory Analysis of Biological Evidence and the Role of DNA in Sexual Assault Investigations](#).

¹⁹ This corroboration would not necessarily require a DNA test, or even trace analysis, to prove that the hair came from the victim. It could simply be based on the victim’s statement about the suspect’s behavior and a visual inspection of the hair indicating it is similar in appearance to the victim’s hair and consistent with the crime scene and victim’s statement (e.g., on the floor near the assault location).

Hair Evidence: DNA vs. Trace Analysis

To illustrate the limits of trace evidence, a forensic laboratory might report the following results after analyzing hair samples. In this scenario, the victim said the suspect pulled out a chunk of her hair during the assault, and also that he used Vaseline as a lubricant. A single hair was found in a jar of Vaseline recovered from the crime scene.

The hairs collected from the crime scene were medium to dark brown in the root area, changing to light brown/blonde down the length of the hair to the tip. The hairs appear to have been chemically treated. All the roots are stretched indicating forcible removal. One hair in this sample is a dark brown/black curled hair, less than one centimeter in length. This hair has no root. The hairs recovered from the crime scene were compared to the hairs collected from the victim (the victim's hair standards were snipped). The long, light brown/blonde hairs are similar in color, including the presence of color treatment, diameter, length and overall condition to the head hair standard from the victim.

The single dark brown/black hair found in the jar of Vaseline is not similar to the victim's hair standard.

In other words, trace analysis of hair can have value, but only if investigators and prosecutors understand its purpose and recognize what can and cannot be concluded on its basis. In this case, the analysis suggested that the victim was excluded as the source of the single hair found in the Vaseline. If a suspect is identified in this case, the crime laboratory could conduct the same analysis from a hair standard taken directly from the suspect – to compare with the hair found in the jar of Vaseline. However, the analysis could not definitively establish the source of the hair as belonging to the suspect (or in fact, to anyone else).

The chunk of hair also corroborates the victim's statement that the suspect pulled it out during the assault. As noted above, this helps to establish the element of force and challenges the suspect's statement that the sexual contact was consensual.

DNA Reference Standards

Regardless of the source of foreign DNA in a sexual assault investigation, it can only be identified as belonging to the perpetrator if it can be distinguished from DNA belonging to the victim and any consensual sexual partner of the victim's. Therefore, comparative analysis of DNA evidence also requires submitting a reference standard from the victim, the suspect (when legally permissible), and any consensual partner of the victim's. Buccal (inner cheek) swabs are the preferred source for these reference standards; however, a blood sample is an option if it is medically or forensically necessary. For example, if the suspect forced his penis in the victim's mouth, and possibly ejaculated, a buccal swab of the victim's inner cheek could produce a mixed sample whereas blood drawn from the victim would not (*National Protocol*, pp. 104-5).

Excluding a Consensual Sexual Partner

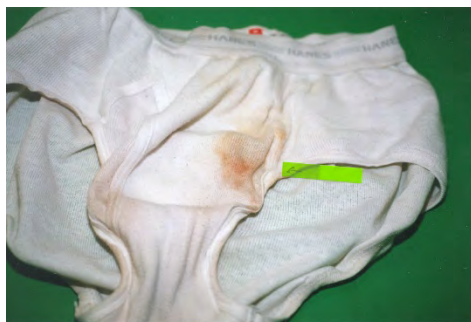To exclude a consensual sexual partner as the source of any foreign DNA profile, the process begins by asking victims if they have had consensual sex within a certain number of days before the medical forensic examination. The reason for this question must also be explained, so victims understand that the purpose is to exclude any consensual partner from the investigation and not to undermine the victim's credibility.

The timeframe for recent consensual sex should generally be the same as the cutoff for conducting a medical forensic exam with a victim following a sexual assault. For example, many communities now use 120 hours (five days) as a guideline, which was the recommendation for best practice in the 2013 edition of the *National Protocol*. In light of emerging research and advances in DNA analysis, however, some states are now moving toward a guideline of seven days (168 hours). Again, whatever cutoff is used for conducting an exam after a sexual assault for victims, the same timeframe should be used for determining whether a reference standard is needed from a consensual sexual partner.

This question about consensual sexual activity will typically be asked by the forensic examiner, but it may also be asked or at least confirmed by investigators. Law enforcement will then seek to obtain a reference standard from the consensual partner as soon as possible, so their DNA profile can be excluded from the investigation. Depending on the nature of the relationship, and any changes over time, a consensual partner might be less inclined to provide a reference standard at a later point.

Clothing Evidence

Clothing often has probative evidentiary value in a sexual assault investigation because of what can be recovered from it, even after a long period of time. It provides a surface upon which biological or trace evidence might be found, such as semen, saliva, blood, hairs, fibers, soil – even in minute amounts. Such evidence can potentially **identify (or exclude) suspects**, based on DNA analysis. It might also **corroborate case facts** – for example, if biological or trace evidence found on their clothing links the victim and/or suspect to each other, and/or to the location of the assault.




Evidence Found on Clothing

One reason clothing can be particularly useful in a sexual assault investigation is because – while foreign matter can quickly wash or wear off the body – the same substances often can be found intact on clothing for a considerable length of time following an assault.

Consider a case where the victim states that an unidentified suspect used a condom during the assault and sucked on her breast. If the victim reports within a few hours or

days and has not bathed since the sexual assault, a swab from her breast may be the best source of evidence. However, if the victim has bathed or isn't able to report for several days or weeks, the best source of evidence may be her bra. If the bra has not yet been washed, it would likely provide evidence of the suspect's DNA from his saliva. This DNA evidence may even be recovered if the victim has washed her bra. Amazingly, with today's technology, DNA has been successfully recovered from clothing that has been washed or dry-cleaned.²⁰



Semen Evidence on Clothing

The San Diego Police Department's Sex Crimes Unit and DNA laboratory participated in research to determine how often semen was found on the clothing of victims of sexual assault (Cain, 2002). This study analyzed 25 cases involving adolescent victims (ages 14 to 17) and 51 cases with adult victims (18 years and older). The results may come as a surprise.

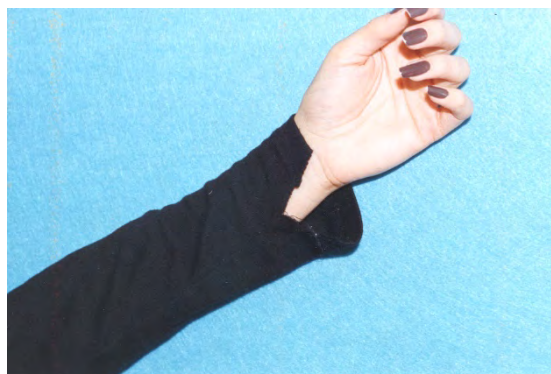- In the adolescent cases, semen was found on the victim's underwear in 62% of cases where the underwear was examined by a criminalist. In fact, the most common piece of crime scene evidence associated with suspect identification in these cases was DNA analysis of semen found on the victim's underwear. Semen was also found on the victim's pants, shorts, or skirt in 38% of cases where they were examined by a criminalist.
- In the adult cases, semen was found on the victim's underwear in 40% of cases where the underwear was examined by a criminalist and on the victim's pants, shorts, or skirt in 29% of the cases where they were examined.

Clothing Itself as Evidence

What is less commonly understood about clothing evidence is that *the clothing itself* can often provide valuable evidence.

²⁰ DNA profiles have been recovered from samples of blood (Klein et al., 2018), semen (Brayley-Morris et al., 2015) and saliva (Breathnach et al., 2015) on laundered clothing, using a variety of evidence collection techniques, including mini-tape lifting (Hess & Haas, 2017).

- For example, the victim's clothing might **corroborate the use of force**, if it is torn or soiled from a physical struggle with the suspect, or if it is damaged in some other way (for example, a button is ripped off or the elastic is stretched). Similarly, torn or damaged clothing from the suspect might indicate signs of force, whether used by the suspect to commit the sexual assault or by the victim to physically resist.



- Clothing may also **corroborate other case facts**. For instance, if the victim describes having struggled with the suspect on the grass, grass stains on the clothing of the victim or suspect may be used to corroborate this fact.

Items Collected with Clothing

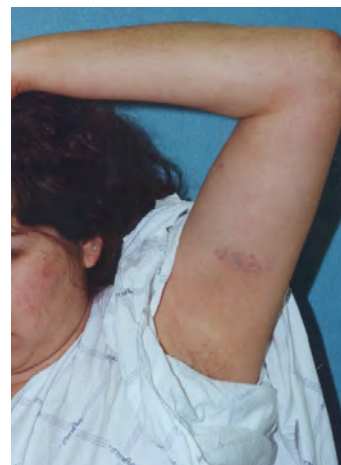As victims and suspects disrobe during a forensic examination, other items worn during or immediately after the assault are often collected. For example, a condom might be found in the suspect's pocket or underwear, or the victim might have worn a tampon or sanitary pad at the time of the assault or immediately afterward. Items connected to the assault may also be brought to the examination and given to the forensic examiner or investigator, such as additional clothing, bedding, used condoms or condom wrappers, tissues used by the victim or suspect to clean up following the assault, or objects that assailants inserted into the victim. Like clothing, these items are valuable to an investigation, not only due to what might be recovered from them but also in and of themselves.



These items may **corroborate the victim's or suspect's account of the assault**, and they may contain biological material that **identifies (or excludes) the suspect and establishes sexual contact**.

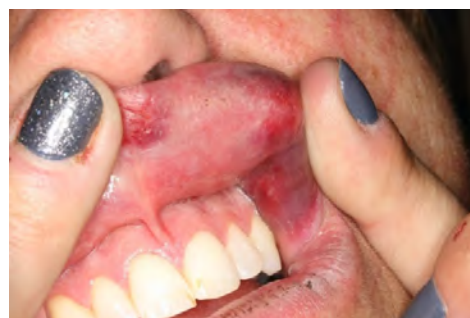Photographic Evidence

Photographs can be critical to the success of an investigation and prosecution of sexual assault, as well as other crimes against persons. This is true for photographs of both the victim and suspect. Although photographs (both genital and nongenital) are a standard component of the forensic examination conducted by a health care professional, nongenital photographs are also frequently taken by law enforcement of both victims and suspects when investigating sexual assaults, as well as numerous other crimes.



Nongenital Photographs

Photographs of nongenital injuries can support an investigation by **corroborating statements** made by the victim, suspect, or witness, as well as **establishing the element of force**. For example, victims may say that the suspect forcefully covered their mouth with a hand to prevent them from calling for help. This type of assaultive behavior can result in injuries to the mouth and frenulum.



Injuries documented on the suspect's body can also corroborate the victim's account of forceful physical resistance, as well as demonstrating the level of force involved.

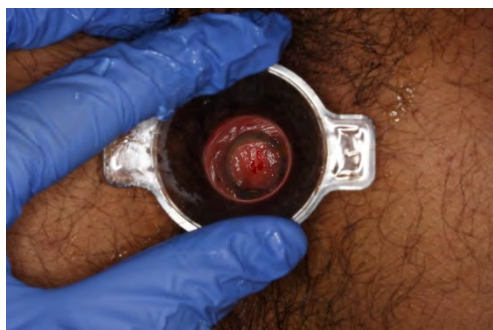

Power of Photographs

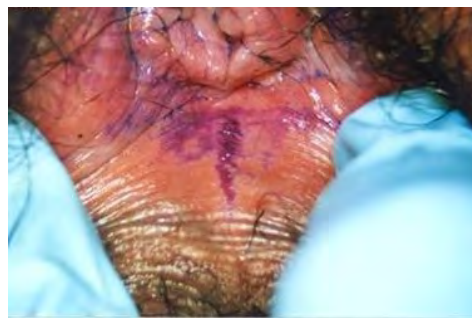The old saying that “a picture is worth a thousand words” may never be more true than when law enforcement is seeking to obtain an arrest or search warrant, or encouraging a prosecutor to file charges. Photographs can convey the reality of forceful injuries in a way that words cannot. Nongenital photographs can also be used as evidence during bail considerations, a criminal trial, or civil litigation.

Genital Photographs

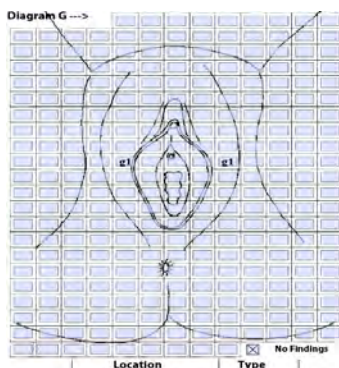
Photographs of genital injury – on the victim or suspect – can potentially achieve the same purposes as nongenital photographs (**corroborating statements, establishing force**). They can also help to **establish the sexual act(s)**. However, the same purposes are often better met with body maps or diagrams, which are typically included in the forensic examiner's report; they are less sensitive than photographs, and they do not typically need to be explained and interpreted by a trained forensic examiner.



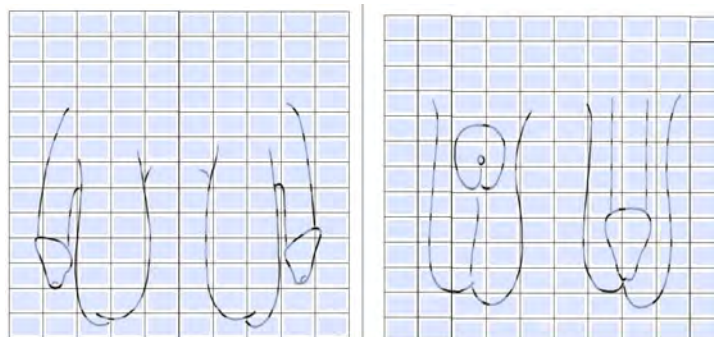
Two bloody lacerations present in the rectum.



Laceration at 6 o'clock on the posterior fourchette going up into the fossa navicularis. Positive blue dye uptake. Abrasion from 5-8 o'clock with pattern circle at 7 o'clock. Positive dye uptake.



Female Genital Diagram



Male Genital Diagrams

Toxicological Samples

Toxicological samples are typically considered for analysis when a victim's voluntary alcohol or drug use becomes an issue during the investigation and prosecution, or when it is suspected that the assault may have been facilitated with the voluntary or involuntary administration of alcohol and/or drugs. Toxicological analysis might also be requested for *suspects* in certain scenarios. This type of toxicological analysis typically requires that blood and/or urine samples are collected within five days of ingestion.

Investigative Purposes

Laboratory analysis of toxicological samples may help **corroborate or challenge statements made by the victim, suspect, or any witnesses**. Also, the presence of alcohol and/or drugs in the victim's system may help to **establish incapacitation** at the time of the assault. Even if the level of alcohol or drug use is insufficient to render the victim incapacitated, it may have contributed to the victim's vulnerability in the situation.

Documentation of whether the victim drank or took drugs *after the sexual assault* may also be important, as it too can **corroborate or refute the facts of the case**.

However, keep in mind the timeframes for alcohol and drugs to be eliminated from the body. If the examination is conducted outside that timeframe, the toxicological analysis will usually not be able to detect their presence. Corroboration will then depend on statements made by the victim, suspect, and any witnesses, as well as other types of evidence (photographs, cell phone and surveillance videos, bar tabs, etc.).



EVAWI's OLT module, [Law and Investigative Strategy: What Kind of Sexual Assault is This?](#) can help investigators determine not only which specific criminal offenses were committed in different sexual assault scenarios, but also frame the investigative strategy based on the defense that is most likely to be raised.

Samples Collected as Routine Protocol?

Some jurisdictions routinely collect blood and urine on all victims and suspects during a forensic examination, because investigators usually do not know enough about the investigation at the point of a forensic examination, to determine whether drugs or alcohol might be relevant. For example, most people think of toxicological analysis for the purpose of establishing the victim's level of incapacitation at the time of the sexual assault. However, it can also be used to address challenges to the victim's credibility.

Many sex crimes investigators will say that the best way to make a sexual assault case "go away" is to suggest that the victim used drugs or alcohol at the time. All too often, this is enough to undermine a victim's credibility, regardless of whether it is true. Therefore, toxicological analysis can also be used to establish that the victim *did not* use drugs or alcohol, discrediting any such statement by the suspect(s) or a witness.

Other jurisdictions do not collect toxicological samples unless a drug or alcohol facilitated sexual assault is suspected, so it is important to consult local policies and procedures on this matter. Regardless, law enforcement agencies should have a clear policy against charging victims for being under the influence of a controlled substance whenever toxicological analysis is conducted during a sexual assault investigation.

Regardless of whether blood or urine are collected routinely, toxicological testing should only be conducted where this is warranted based on medical purposes (for health care providers) or investigative and prosecution purposes. Toxicological testing is not recommended as a routine practice (*National Protocol*, p. 108).

Testing for Medical vs. Forensic Purposes

It's also important to recognize the various professional roles and responsibilities with respect to toxicological testing. Just as with DNA evidence, the role of a forensic examiner is to collect samples for toxicological analysis, but *not to screen or test the evidence for investigative purposes*. There are a number of reasons for this. For one, medical laboratories do not follow a chain of custody which is required for evidence in a criminal investigation. They are also typically unable to test samples at the very low levels of detection required for a sexual assault investigation. Therefore, law



enforcement agencies must have policies and procedures in place to ensure that toxicological samples are tested at a toxicology laboratory for forensic purposes.

At the same time, it is important to note that health care providers often request toxicology tests *for medical purposes*, during the course of diagnosis and treatment for a patient. When this is done, investigators may seek to obtain a release from the victim/patient for the associated medical records (if this is appropriate and relevant given the case facts), so that any findings can be incorporated into the investigation.



For more information, see the [Fact Sheet on Drug-Facilitated Sexual Assaults](#) on the Recommended [Minimum Performance Limits for Common Drug-Facilitated Crimes](#) published by the Drug-Facilitated Crimes Committee of the Society of Forensic Toxicologists (SOFT).

Voluntary Drug and Alcohol Use

Many state laws recognize that victims who are extremely intoxicated by alcohol or incapacitated by drugs cannot legally consent to sexual activity, and therefore sexual contact or penetration is a crime even if no force, threat, or fear is used. In these situations, a toxicological analysis of the victim's blood or urine can demonstrate the extreme level of incapacitation that rendered the victim unable to consent to sexual activity. The results can therefore challenge any statement that victims drank or used just enough drugs to overcome their sexual inhibitions or to generally discredit them.

Yet some state statutes require that the victim's incapacitation is *involuntarily induced* to qualify as first degree or forcible rape. In other words, the element of incapacitation is not met if the victim *voluntarily chose* to consume drugs or alcohol. (However, it is still possible that other criminal offenses can be investigated and potentially charged, for example, a lesser degree of rape, such as sexual battery, or false imprisonment, etc.)

Regardless of the state statute, it is always important to document whether the suspect or others administered drugs or alcohol to the victim without the victim's knowledge or consent, or whether the victim was pressured or coerced into consuming drugs or alcohol. These facts can help to paint an accurate picture of the event, and even in states that do not require the suspect to administer the drug to incapacitate a victim, additional charges may be considered (such as poisoning, contributing to the delinquency of a minor, or committing a felony in the commission of another felony).



AEquitas: The Prosecutors' Resource on Violence Against Women offers a [Statutory Compilation of Rape and Sexual Assault Laws \(May 2012\)](#), which includes a summary of provisions relating to drug- and alcohol-facilitated sexual assault (pp. 90-97). It addresses voluntary versus involuntary incapacitation, and also lists those states that prohibit sexual activity when the perpetrator knows or should have known that the victim was incapable of consenting.



Examples of Potentially Probative Evidence

To close this section, let's review multiple case scenarios where evidentiary samples and items collected from victims or suspects might produce probative results.

Evidence Collected from Victims

First, several examples of potentially probative evidence collected *from victims*:

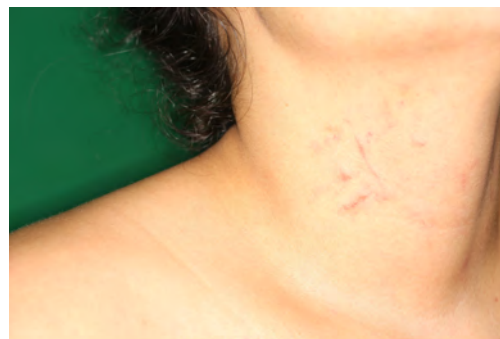- A suspect penetrates the victim's vagina, anus, or mouth with his penis, and ejaculates. Crime laboratory analysis of swabs taken from the victim's orifices, as well as clothing, may indicate the presence of semen.
- A suspect ejaculates on a body surface of the victim (e.g., stomach, breasts). Semen may be recovered from swabs taken from stains or substances on the victim's body surface or clothing.
- A suspect has oral contact with the victim's body surfaces, including orifices. Contact may include kissing, biting, sucking, or licking. In this scenario, the suspect's saliva may be recovered from swabs taken from body and clothing locations the victim indicated the suspect had oral contact. Bite and suction marks may also be documented.
- The victim describes scratching the suspect and ripping the suspect's jacket. Swabs from the victim's fingers and underneath the fingernails may contain biological material from the suspect. Also, fibers from the ripped jacket may be found either on the victim or at the crime scene.
- The victim is forced to digitally penetrate the suspect's anus or vagina. Again, biological material from the suspect may be found on swabs taken from the victim's fingers or underneath the fingernails.
- A male victim is forced to penetrate the suspect's anus or mouth with his penis. Biological material from the suspect may be recovered from the victim's penis and/or scrotum.

Evidence Collected from Suspects

Probative evidentiary samples and items may also be found on the body or clothing of *suspects* during a forensic examination. For example:

- A suspect penetrates the victim's mouth with his penis, but the victim does not believe he ejaculated. Semen will probably not be recovered from the victim's mouth; biological evidence from the victim is more likely to be found on the suspect's penis and scrotum.

- Alternatively, the suspect ejaculates in the victim's mouth, but the victim washes out her/his mouth or brushes her/his teeth. Again, semen is not likely to be recovered from the victim's mouth, but biological material from the victim may be found on the suspect's penis and scrotum.
- A suspect penetrates the victim's vagina, anus, or mouth with his penis, but he uses a condom – and the condom is not recovered. Because the suspect's ejaculate will typically be deposited in its entirety in the condom, the suspect's scrotal swab should be examined for biological material from the victim (e.g., vaginal secretions, epithelial cells). It is also common for female fluids and cellular material to accumulate on the penile surface not covered by the condom.
- A suspect penetrates the victim's vagina or anus with his penis, but he does not ejaculate. Biological material from the victim might be found on the penile and scrotal swab collected from the suspect.
- A male victim is forced to penetrate the suspect's orifice with his penis, and the victim ejaculates in or on the suspect's body. The victim's semen may be recovered from the suspect's body or orifice.
- The suspect digitally penetrates the victim's vagina or anus. In this scenario, biological material from the victim may be found on the suspect's fingers or underneath the suspect's fingernails.
- The victim is injured during the sexual assault, and blood is found on the suspect's body or clothing. Alternatively, the victim may report fighting the suspect, and scratches, bite marks, or other signs of injury may be found on the suspect's body. The suspect's or victim's clothing may also be damaged in the struggle.



Once again, investigators must assess the totality of evidence and information gathered in a sexual assault case, to inform investigative strategies and decisions.

Identification and Documentation of Injury

Nongenital Injuries

The nongenital examination of victims and suspects is sometimes referred to as a general “head-to-toe” evaluation or assessment. This usually includes an inspection of the body, an observation of patient characteristics, and documentation of findings such as injuries. Examples of these characteristics and potential injury findings are provided in Appendix C, in a chart adapted from the *National Protocol – Pediatric* (pp. 138-139).

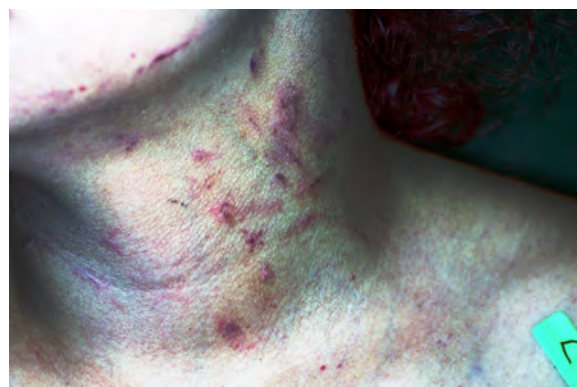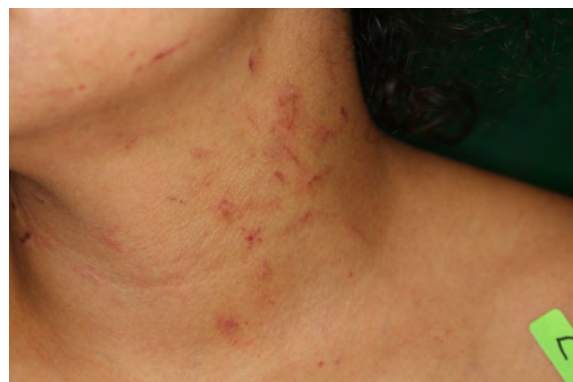Location of Nongenital Injuries

Forensic examiners must have knowledge about the common pattern of nongenital injuries resulting from sexual violence, so they can ask appropriate questions and locate injuries based on the assault history (Ledray, 1999; Sheridan, 1993). This knowledge is also helpful for investigators to form questions for victims and to be aware of where to look for injuries. For example, some common nongenital injuries include the following:

- Neck bruising and scratches (strangulation);
- Blunt traumatic injuries to the head, face, torso, or limbs, and penetrating injuries;
- Defensive injuries, such as lacerations, abrasions, and bruises, on the hands and the extensor surfaces of the arms and medial thighs; and Other minor injuries, such as bite marks (Linden, 2011).

Additional nongenital injuries that might be found on victims, especially when domestic violence is involved, include:

- Whip or cord like injuries to the back;
- Missing sections of head hair from being pulled or dragged by the hair;
- Punch or bite injuries to the breasts and nipples;
- Punch and kick injuries to the abdomen;
- Punch and kick injuries to the thighs; and
- Facial bruising, abrasions, and lacerations (Ledray, 1999; Sheridan, 1993).



Second photo is of the same woman, with a negative invert filter used to enhance visibility of injuries in the photograph.

Prevalence of Nongenital Injuries

While early research on adult and adolescent victims found that nongenital injuries from sexual assault were relatively rare, more recent research suggests somewhat higher rates. The range is now from 35% to almost 82%, depending on the population sampled and the methodology used.²¹ However, few female or male victims present to medical

²¹ In one study of 153 women who had a sexual assault examination, 46% had nongenital injuries (Palmer et al., 2004). In another study of 1,076 cases of sexual assault victims presenting to an urban

providers with severe or life-threatening injuries (Casali et al., 2017; Poarch & Faugno, 2017; Ruxana et al., 2015; Williams & Bierie, 2015; Zilkens, Smith, Kelly et al., 2017).²² Also, many have no visible nongenital injuries at the time of the forensic examination.



Pattern of Nongenital Injuries: Type and Location

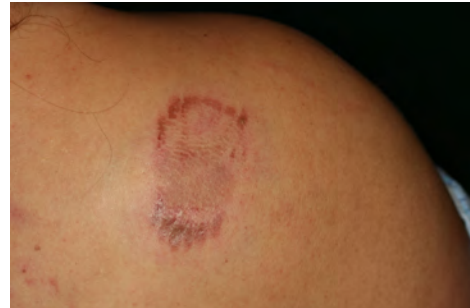In one study of 314 sexual assault cases, Valentine and Miles (2014) sought to determine the pattern of nongenital injury among victims. “Pattern of injury” refers to the general description of where injuries are observed; in other words, whether these injuries can be observed in a pattern of specific sites on the victim’s body.

These researchers found that the most common types of nongenital injuries documented were: bruises (66%), abrasions (44%), redness (28%), petechiae (15%), swelling (12%), discolored marks (10%), and lacerations (6%). Only 1% or fewer had ecchymosis, puncture wounds, incisions, bite marks, conjunctival hemorrhage, missing or broken teeth, or bone fracture. As for location, the most common sites for nongenital injuries included the extremities such as the arms and legs (73%), chest or back (over 30%), head or neck (20%), and breasts or abdomen (14%).

Patterned Nongenital Injuries

The term “patterned injury” is different from “pattern of injury” discussed above. While “pattern of injury” refers to the location of injuries on a victim’s body, “patterned injuries” are seen when an object is used to inflict injury on a person, and the injury that is left on the body can be used to identify the object that might have been used.

For example, if the victim was struck by a coat hanger, burned by an iron, whipped with an extension cord or belt, or punched by a suspect



Bite mark on top of left back shoulder area

emergency department, general body trauma was detected on 67% of victims (Riggs et al., 2000). In a third study of 819 female victims 15 years or older presenting to an emergency department, 52% had general body trauma (Sugar, Fine & Eckert, 2004). In a retrospective report on 1,699 medical forensic examinations, Rosay and Henry (2008) found nongenital injuries recorded for 52% of sexual assault victims. The most common sites were the arms and legs. In a report from Valentine and Miles (2014), of 314 sexual assault case charts reviewed from the Utah Department of Public Safety’s Crime Laboratory, almost 82% of victims had nongenital injuries. Finally, in a retrospective study of 57 *male victims*, extragenital injuries were recorded in 35% of cases; abrasions and perianal reddening were the most frequent acute genital marks, whereas the head and lower limbs were the body parts most commonly affected by blunt trauma (Casali et al., 2017).

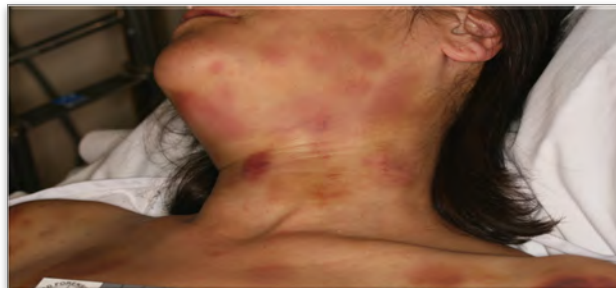²² In two large-scale studies of adult female victims, one found that 2% had “severe” injuries (Zilkens et al., 2017) and the other found no “significant” injuries in the sample (Ruxana et al., 2015). Another small-scale study of adult male victims found no clinically “severe” injuries (Casali et al., 2017).

wearing a large ring, the victim's injuries may be used to identify the object that was used to inflict the injury.

Bite marks on the victim's or suspect's body represent another kind of patterned injury and it is important that they are described in reports to law enforcement, and swabs collected from them (to analyze for DNA evidence from saliva).

Strangulation Injuries

Strangulation may also produce a patterned injury, but there may be no visible injury at all. Most assailants who strangle their victims use their dominant hand, so the fingertip pattern that is left on the victim's neck can often help to identify whether the assailant is right- or left-handed. In addition, a right-handed assailant will usually grab the victim's anterior neck, leaving a single thumbprint bruise on the right side of the victim's neck and several fingertip bruises on the left side of the victim's neck (Ledray, 1999; Sheridan, 1993). This pattern of injury can say a lot about how the violence was perpetrated.



Not surprisingly, research points to a strong association between intimate partner violence and nonfatal strangulation during sexual assault (International Association of Forensic Nurses, 2016; Mcguown et al., 2016, Shields et al., 2010; Zilkens et al., 2016).



Indicators of Strangulation

To help assess for strangulation, the International Association of Forensic Nurses (IAFN) offers a [Non-Fatal Strangulation Documentation Toolkit](#), which instructs forensic examiners to examine the head, face, neck, and chest for areas of erythema,²³ petechiae,²⁴ abrasion, contusion, swelling, laceration, incised wounds, fractures, bite marks, burns or tenderness. Specifically, they are to note:

- Voice changes: Dysphonia (defined as hoarseness) or aphonia (defined as severe or complete loss of voice)
- Swallowing changes and tongue swelling: Dysphagia (defined as difficulty swallowing) or odynophagia (defined as painful swallowing)
- Breathing changes: Dyspnea (defined as difficulty breathing)

²³ Erythema is defined as redness of the skin or mucous membranes produced by congestion (dilation) of the capillaries. However, there are many causes of erythema other than trauma.

²⁴ Petechaie occur when tiny blood vessels (capillaries) break open and blood leaks into the skin

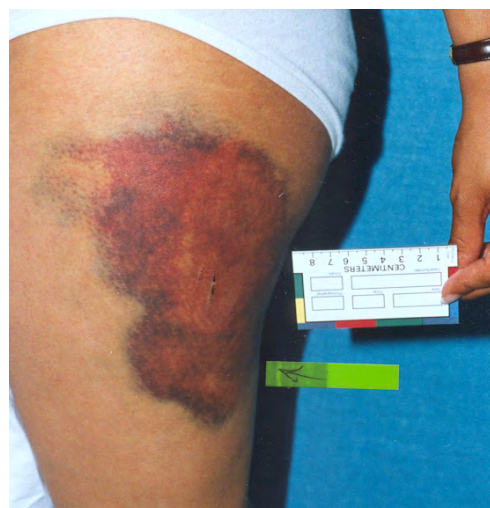
- Visible injuries on the neck and mastoid: Ligature marks/edema/abrasions (scratches and scrapes)/erythema/contusions
- Petechiae: Eyelids/peri-orbital region/face/scalp/neck/ears/soft palate/under tongue
- Subconjunctival/Scleral hemorrhage/Scleral edema (eyes)
- Neurological findings: Ptosis/facial droop/unilateral weakness/loss of sensation/paralysis/seizure
- Neck swelling: Measurement (in centimeters) for size and follow-up consultation to assess changes
- Miscarriage or pregnancy: Fetal heart rate/last menstrual cycle
- Lung injuries: Aspiration pneumonia/pulmonary edema
- Other symptoms: Acid reflux, etc.
- Pain, swelling, erythema, contusion, abrasion, petechiae, bite marks, knife wounds, or gunshot wounds on any other area of the body (i.e., chest, back, upper extremities, lower extremities)



Another resource for assessing and documenting strangulation is Faugno, Trujillo, Bachmeier and Speck's (2017) book, *Manual Nonfatal Strangulation Assessment for Healthcare Providers and First Responders*. For additional information on the prevention, investigation, and prosecution of strangulation, please see the [Training Institute on Strangulation Prevention](#).

Bruising

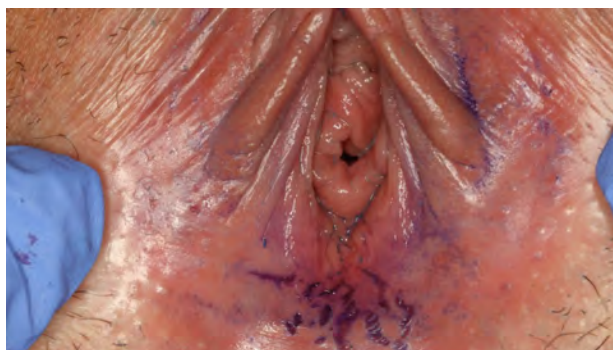Bruises can sometimes constitute patterned injury, depending on how the injury was sustained. However, bruising cannot be dated by its color; there is simply too much variation based on patient age, health, medications, and other factors (Byard & Langlois, 2015). The color of a bruise is just one piece of the physical assessment rather than the sole criterion to estimate age of bruising. Forensic examiners can only conclude that the bruise's appearance is consistent with, or not consistent with, the history of when the trauma was inflicted.



- Bruises tend to show multiple colors as they heal (Riviello, 2014). In general, red and purple bruises tend to be fresh and then they progress to blue, to brown, and then to yellow or green. However, bruise discoloration and changes over time on a specific person can be affected by multiple factors, such as medication use, type of tissue injured, skin tone, gender, age, disease, depth of injury, and inflicting object characteristics (Nash & Sheridan, 2009).
- Given these variables, Nash and Sheridan suggest that a conservative estimate of a bruise's age as newer versus older could be given, when combined with other exam findings. For example, a red, painful bruise with well-defined margins that is hard or firm to the touch, is more consistent with a history of recent injury than a bruise that is yellow, nonpainful, soft, and with blurred margins.

Genital Injuries

Genital trauma refers to tissue injury in the genital region – including the perineum, anus, and genital area. Genital injury results from the disruption of the protective covering of this region, and it is explained with descriptors such as: *abrasions* (defined as macro and micro trauma of superficial epidermal surfaces); *lacerations* (with severity related to dermal depth); and *bruising* (including petechiae to hematoma, crushing or glancing without skin breakage).



Multiple lacerations from 5-7 o'clock on posterior fourchette going up into the fossa navicularis with positive blue dye uptake. Linear abrasion with positive blue dye uptake on left labia minora/majora sulcus.

Genital injuries can **indicate the use of force** during a sexual assault, provide **evidence of recent sexual contact**, and **corroborate the facts of the assault**, if they are consistent with victim, suspect, and/or witness statements.

Appendix D summarizes the genital anatomy typically inspected during a victim and suspect forensic examination. The chart is adapted from the National Judicial Education Program (2002). Appendix B also provides related anatomical illustrations.

Location of Genital Injuries

The most common locations for genital injury in teenage girls and women include the posterior fourchette, labia minora, hymen, and fossa navicularis (Grossin et al., 2003; Jones, Dunnuck et al., 2003; Lauber & Souma, 1982; Rosay & Henry, 2008; Slaughter & Brown, 1992; Slaughter et al., 1997; Sommers, 2007; Sommers et al., 2001; Valentine & Miles, 2014). The posterior fourchette is the first point of contact when the penis enters the vagina, and it is also the point of greatest stress when forceful

stretching occurs. It is therefore not surprising that it is the most common site of genital injury among sexual assault victims.²⁵



Despite common misconceptions, the hymen is not always injured when a female first experiences sexual intercourse, regardless of whether it is consensual or nonconsensual. Some women even have intact hymens after childbirth. This entertaining yet impactful [4-minute video](#) produced by College Humor provides information about the hymen, including debunking this myth.

For male victims, common locations for genital injury include the external genitalia (penile shaft and glans) and scrotum; and anal (anus and rectum). One study found that 2% of those receiving a medical forensic examination had injuries on/in the anus, and 0.3% had injuries to the rectum (Valentine & Miles, 2014).

As for the type of genital injuries, some experts summarize them with the acronym “TEARS,” which refers to tears, ecchymosis (bruising), abrasions, redness, and swelling (Slaughter, 2013). About 70% of genital injuries detected during victim examinations are characterized as micro trauma such as abrasions, lacerations, and bruising (communication with D. Faugno, 8/2017).²⁶

THE MALE EXTERNAL GENITALIA

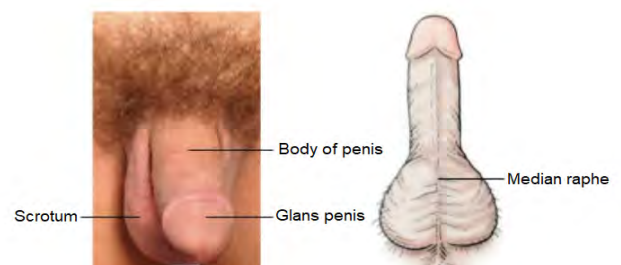


Photo Credit: Arturo, Decano, Associate Professor, St. Luke's College of Medicine

Prevalence of Genital Injuries

As with nongenital injuries, the rate of genital injuries documented among female sexual assault victims who have a medical forensic examination also varies widely. For

²⁵Among the sexual assault victims who had documented genital injury in the study by Slaughter et al. (1997), 70% had injury to the posterior fourchette, 53% to the labia minora, 29% to the hymen, and 25% to the fossa navicularis. Jones, Rossman et al. (2003) reported similar findings among 766 women and pubertal girls younger than 18 years old. They found that 78% had injuries at one of the four locations listed above, although adult women experienced less injury to the hymen and greater injury to the perianal area as compared to girls. In Valentine and Miles' (2014) study, location of genital injuries on female victims included: fossa navicularis (38%); labia minora (14%); anal/rectal (13%); labia majora (12%); posterior fourchette (12%); perineum 10%; cervix 7%; peri-hymenal tissue (7%); inner thighs (7%); vagina (6%); hymen (2%); and periurethral tissue/urethra (1%). In Rosay and Henry's (2008) study of sexual assault victims seeking forensic care (98% of whom were female), the most common sites of genital injury included the posterior fourchette, the labia minora, the perineum, the fossa navicularis, and the anus.

²⁶ In a study by Valentine and Miles (2014) the following types of genital injury were identified for both female and male victims: abrasion (42%), laceration (32%), redness (22%), bruises (6%), swelling (3%), petechiae (2%); discolored mark (1%), avulsion (<1%), and puncture wound (<1%). In Rosay and Henry's 2008 study of sexual assault victims seeking forensic care (98% of whom were female), the most common genital injury type was laceration.



example, Sommers (2007) noted rates from 5% to 90%. There are a number of reasons for such wide variation. One of these is the method used to detect genital injury.

Three primary strategies are used to detect injury during the genital examination:

- (1) Direct visualization with the unaided eye;
- (2) Staining techniques, in which toluidine blue dye or fluorescent dye are applied topically to highlight injuries; and
- (3) Colposcopy, or now more commonly, digital cameras, allowing magnification with a light source and digital recording of images of injuries (Sommers, 2007).²⁷

Simply looking at the genitalia or anus with the naked eye is often insufficient for identifying genital injury (Markowitz & Scalzo, 2011). Therefore, the use of advanced visualization techniques (such as staining and digital magnification of injuries), offer forensic examiners additional “tools” to detect injuries.^{28 29} Along with standardized training for forensic examiners, these tools have resulted in higher prevalence rates for genital injury documented over time in literature (Carter-Snell, 2007; Sommers, 2007).

²⁷ Most forensic examiners now use digital cameras for advanced visualization rather than colposcopes.

²⁸ Another visualization tool sometimes employed with adolescent sexual assault victims is the Foley catheter. Jones, Dunnuck et al. (2003) found a 50% increase in identifying genital injury when using a Foley catheter with adolescent victims. With this technique, an inflated balloon in the distal vaginal vault puts pressure on the hymen, effectively stretching it out and allowing for a more accurate view of the hymen edges (Jones, Dunnuck et al., 2003).

²⁹ If rectal penetration is reported or suspected, an anoscope is sometimes used to identify and evaluate trauma. It may also be used to help obtain anal swabs and trace evidence (*National Protocol*, p. 98).

It makes sense to focus on rates from studies in which advanced visualization techniques *and* direct inspection are used to detect genital injury. When these studies are examined, the rate of genital injury among sexual assault victims ranges from 23-87%. The rates are considerably lower (6-13%) for women who have a medical forensic examination but no clear recollection of the sexual assault,³⁰ but higher even in those cases where advanced visualization techniques are used. However, even with such techniques, there are many cases where genital injuries are not detected.

Factors that Impact Genital Injury Identification

Several factors influence the likelihood of whether genital injury will be identified among victims of sexual assault. These include the following:

- **Timing of the examination** can affect the detection of genital injuries, as they often heal rapidly. Perhaps not surprisingly, research documents that genital injuries are more likely to be observed among victims who have a medical forensic examination within 24 hours of the sexual assault (Slaughter et al., 1997; Sugar, Fine & Eckert, 2004).^{31 32}
- **Factors related to age** can also play a role. Research suggests that women under age 18, or past the point of menopause, are more likely to have genital injury than other women (Carter-Snell, 2007; Faugno et al., 2016; Grossin et al., 2003; Poulos & Sheridan, 2008; Sugar, Fine & Eckert, 2004; Zilkens, Smith, Phillips et al., 2017).³³ This is explained by the lack of estrogen in prepubescent girls and post-menopausal women not using hormone replacement therapy. Estrogen promotes elasticity in genital tissues, and this protects against injuries resulting from sexual activity (whether consensual or nonconsensual).

³⁰ Sachs and Chu (2002) reported genital injury prevalence of 81% among 209 sexual assault victims. Similarly, a study of 766 victims found genital injury in 83% of adolescent girls and 64% of adult women (Jones, Rossman, et al., 2003). In a retrospective analysis of 3,356 sexual assault victims at least 12 years old, a little less than 50% had documented genital injury (Drocton et al, 2008). In another retrospective report on 1,699 victim examinations, Rosay and Henry (2008) found genital injuries recorded for 41% of victims. The Valentine and Miles report (2014) found 67% of 314 victims had genital injuries. Baker and Sommers (2008), in a retrospective review of 234 medical records of women aged 14 to 29 years from an emergency department sexual assault program, found that almost 63% had genital injury. McLean et al. (2011) reported that almost 23% of 500 victims of penile-vaginal rape sustained genital injury. Similarly, in a study by Zilkens, Smith, Phillips et al. (2017) of 1,266 women seeking sexual assault forensic care, genital injury was detected in 24% of those reporting completed vaginal penetration, and 13% of women with no clear recollection of the sexual assault. In addition, anal injury was detected in 27% of women reporting completed anal penetration as well as 6% of women with no clear recollection of the sexual assault (Zilkens, Smith, Phillips et al., 2017). In this study, macroscopic visualization, rather than colposcopy or staining, was used for the genital examination. In a study of 120 female volunteers, Zink, et al. (2010) found that more genital injuries were noted after consensual intercourse, particularly anal penetration, with the use of toluidine blue dye, rather than visualization with the naked eye alone or with magnification.

³¹ Sugar, Fine and Eckert (2004) did not use magnification to visualize injuries in their study.

³² Slaughter et al. (1997) found that, of 213 victims with documented genital injury, 73% were examined within 24 hours of the assault, 8% between 24 and 48 hours, and 19% at or after 72 hours.

³³ One study found that postmenopausal women were over three times more likely to sustain genital injury than premenopausal women following a sexual assault (Morgan, Dill & Welch, 2011).

- Genital injury also appears to be more common among victims **without prior sexual experience** than those with sexual experience (Briggs, Stermac & Divinsky, 1998; Carter-Snell, 2007; Drocton et al., 2008; Sugar, Fine & Eckert, 2004; White & McLean, 2006).
- **Skin color** may impact genital injury identification, as it may be more difficult to detect on darker skin (Sommers et al., 2008, 2009).
- In addition, research points to a link **between genital and nongenital injuries** (Lindsay, 1998; Palmer et al., 2004; Slaughter et al., 1997). In other words, sexual assault victims who have nongenital injuries are more likely to also have injuries to the genitals and/or anus than those without nongenital injuries.

In sum, genital injuries are more frequent in: (1) Victims younger than 20 and older than 49 years; (2) Females who had not previously had sexual intercourse, and; (3) Those examined within 24 hours, and after anal assault (Sugar, Fine & Eckert, 2004).

Genital Injuries of Male Victims

There is much less research available on genital injuries experienced by male victims, partly because they are often more hesitant than female victims to report their sexual assault or seek health care (Larsen & Hilden, 2016). That said, there is some indication that genital injury rates are somewhat higher among male victims who report sexual assault as compared to females. In one retrospective study of 57 male victims (Casali et al., 2017), genital injuries were recorded in over 61% of cases. Earlier studies found rates of 50% to 67% for anal trauma among male victims (Hillman et al., 1991, 1990; Kaufman et al., 1980). Epidemiological data suggest that forcible fondling and sodomy are among the most prevalent forms of male sexual assault (Choudhary et al., 2012).



Exam Findings by Gender

Much of what we know about injuries of sexual assault victims comes from the literature on medical forensic examinations of female victims. More literature on male victims is beginning to emerge. However, there is scant research available on physical findings from examinations of transgender victims or suspects.

Does Genital Trauma “Prove” Sexual Assault?

The question that typically comes up at this point is whether genital injuries documented during a medical forensic examination can be attributed to a sexual assault. Although the research is somewhat equivocal, many experts believe that genital trauma is more

likely to result from sexual assault than consenting sexual intercourse.³⁴ However, others suggest caution linking the two, based on examination findings. For example, Sheridan and Anderson (2012) noted that some studies find differences in injury patterns, types, or locations that may distinguish genital injuries from nonconsensual sex versus consensual sex. However, they conclude that the data do not unequivocally confirm these findings. Thus, they suggest that the presence or absence of genital injury should not be used to render an opinion regarding consent to sexual intercourse.

What if There are No Injuries?

What is the value of exam findings to a sexual assault investigation when there are no visible injuries, or when injury findings are nonspecific (for example, indistinguishable from those sustained as a result of consensual sex)? The reality is that visible physical injuries may not be detected on the bodies of sexual assault victims or suspects – for a number of reasons.³⁵ We cannot stress this enough.

- While genital and nongenital injuries can provide corroborative evidence, their absence does not mean that a sexual assault did not occur, that there was consent to sexual activity, or that force was not used to commit the assault.
- The absence of physical injury also does not equate to the absence of harm. The harmful and long-lasting physical, physiological, and social consequences of sexual assault on victims are well-documented, and they include STIs, pregnancy, trouble sleeping, pain, mental health problems, sexual dysfunction, eating disorders, self-injury and suicide (CDC, 2016; Mason & Lodrick, 2013; Ruxana & Thomas, 2013; Krug et al., 2002).



Two helpful resources that address the impact of sexual assault include EVAWI's OLT module, [Victim Impact: How Victims Are Affected by Sexual Assault](#) and the CDC's [Sexual Violence: Consequences](#).

In sum, the absence of genital and nongenital injury may indicate that: (1) No injury occurred; (2) No injury was visible based on a limited examination; or (3) Injury may have been there, but it has already healed (Markowitz, 2017). When there are no

³⁴ One study found a significant difference in genital injury prevalence between women who were vaginally penetrated with and without consent. Almost 54% of the rape victims, but only 10% of the women in the consensual group, were found to have at least one genital injury. The odds ratio indicated that women who were penetrated without consent were almost 20 times more likely to sustain at least one genital injury than those penetrated consensually (Lincoln et al., 2013). In another study, a low rate of genital injury was found across study samples, but those who were raped were three times more likely to sustain a genital injury than those who had consensual intercourse (McLean et al., 2011).

³⁵ Remember, however, that some groups of victims may sustain more injuries than others. For example, older victims may be more physically fragile than younger victims and thus may be at risk for tissue or skeletal damage and exacerbation of existing illnesses and vulnerabilities (*National Protocol*, p. 36). EVAWI offers a resource page on [elder abuse](#), that includes the National Sexual Violence Resource Center's [Sexual Violence in Later Life: A Technical Assistance Guide for Health Care Providers](#) (Pierce-Weeks, 2013), and a reference sheet, [Bruising in Older Adults](#), from the National Center on Elder Abuse.



injuries, investigators should explore with the forensic examiner any alternative explanations for their absence (a delay of the exam or the type of assault). Alternative explanations can also be discussed for injury findings (such as genital microtrauma potentially caused by other events, including consensual sex or tampon use).

Conclusions from Victim and Suspect Examinations

Now that we have reviewed the many types of findings that could be documented during the forensic examination of a victim and suspect, it is critical to recognize what can and cannot be concluded by a forensic examiner on this basis. These conclusions are summarized below, and then discussed separately for victim versus suspect exams.

**Sexual Assault
and Consent are
Legal Concepts,
Not a Medical
Diagnosis**

- Examiner can verify presence of physical findings
- Can offer conclusion about whether physical findings are consistent with history of the assault
- Neither sexual assault nor consent should ever be diagnosed from the examination

Victim Examinations

Based on the physical findings from a medical forensic examination of a sexual assault victim, examiners can make two primary conclusions:

- Whether there is visible evidence of **sexual contact** and/or **recent injuries/trauma**; and
- Whether there is **consistency** between the physical findings and the victim's account of what happened.

In other words, the examiner can offer a conclusion about the level of consistency between the victim's history (including the account of the assault) and the physical findings from the exam. However, consistency is not confirmation or proof of this history.

The examiner cannot make a judgment whether any sexual contact was consensual, or whether a victim was sexually assaulted or raped. These are legal conclusions, not a medical diagnosis. Consistency simply means that the findings (or lack of findings) *could have resulted* from the events described. This judgment will be based on the examiner's general and forensic training, clinical experience, and the medical and forensic literature, as well as the experience of the examiner's professional colleagues who are often consulted on individual cases and in case review activities.

No Physical Findings

While forensic examiners can conclude that an examination did not produce any visible physical findings (in other words, the findings were within the range of a normal examination), they cannot conclude on the basis of an examination that *there is no evidence in the case*. For example, some injuries cannot be observed visibly; they are only detected after problems persist, and additional examinations are conducted using x-rays, CAT scans, MRI's, etc. This is especially true for injuries to the neck and back.

In addition, some conclusions can only be reached after a forensic analysis of any available evidence by laboratory personnel, such as the victim and suspect's evidentiary kits and associated evidence (like clothing and bedding), the results of toxicological analysis (including the victim's and suspect's blood, urine, or vomit, and substances or containers in a case of suspected drug- or alcohol-facilitated sexual assaults), as well as other crime scene evidence. It would be very inappropriate – and potentially quite harmful – for a forensic examiner or an investigator to tell a victim there was *no evidence*, just because there were no visible physical findings observed and documented during a forensic exam.



The Office for Victims of Crime (OVC), US Department of Justice, produced a 2.4 minute video called, [Evidence-Based Practice](#), which highlights the importance of research and best practices for medical forensic care of victims, including the conclusions that examiners can make based on exam findings.



Let's explore some reasons why an examiner cannot conclude that a victim consented to sexual contact or that they were sexually assaulted.

Do all sexual assaults result in injuries? What about forcible rapes involving penile-vaginal or anal penetration? Do they all result in genital injuries?

Does it matter if the victim had a physical response (e.g., a male victim having an erection or ejaculating while being assaulted, or a female victim responding to the assault with vaginal lubrication or even orgasm)? Does this mean the victim consented?

Does a normal finding, or no physical findings, provide evidence that a sexual assault did not occur?



Suspect Examinations

Forensic examiners also offer a summary of physical findings for law enforcement based on a suspect examination, indicating whether the examination was normal or whether any physical findings were documented that potentially relate to the sexual assault (as opposed to, for example, an old injury). As with the victim examination, it is not the examiner's role to express conclusions regarding whether or not a sexual assault occurred and whether or not the suspect could have been the perpetrator.

While sexual assault is a medico-legal health concern, whether or not such a crime occurred is a matter for the court to decide. The healthcare provider should not express conclusions, or opinions of diagnosis to the suspect or others, nor should any such opinions be written in the record.

US Department of Defense, Suspect Instructions, Sexual Assault Evidence Collection Kit and DD Form 2911, p.1



EVAWI's Expert Interview Series briefly explores [Common Misunderstandings about the Forensic Examination and What You Can Learn from It](#).

Law Enforcement Documentation of Exam Findings

It is important that investigators understand all components of a forensic examination and can accurately summarize exam evidence (including physical findings) in their investigative reports. To accomplish this goal requires building their own knowledge of medical forensic terminology commonly used in sexual assault cases and related anatomy; however, investigators can also look to forensic examiners if they have any questions regarding exam components, physical findings, or other exam evidence. To start, investigators should always document law enforcement's involvement, and any steps taken to facilitate a forensic examination in their own reports of a sexual assault investigation. If no forensic examination is facilitated, the investigator should document the reasons why (for example, a late disclosure, the nature of the assault, or the victim declined).

Taking all the exam findings and presenting them as a single clinical picture increases the value of the examination and the resulting evidence to a law enforcement investigation. Medical forensic evidence is not in and of itself conclusive, but it can be compelling if presented fully.

Markowitz, 2017, p. 18

Key findings from the forensic examination of a victim or suspect should then be incorporated into the patrol officer's initial crime report and the investigator's follow-up documentation. It is not enough to simply document that a forensic examination was conducted and refer to the examiner's report. Investigators must understand and document the findings of a forensic examination as part of their entire investigation, and based on that information, determine what investigative steps should be taken next.

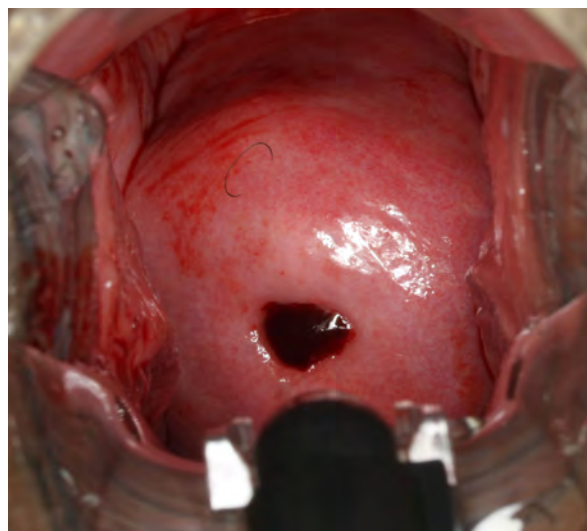


To illustrate how a forensic examination might be documented by law enforcement investigators, we offer the following excerpts, drawn from a variety of police reports. The names of victims and suspects have been changed, but the names of health care providers and other responding professionals have been retained, to credit their work.

Transportation by Patrol

In the first sample, the patrol officer documents transporting the sexual assault victim to facilitate a medical forensic examination, then briefly summarizes the physical findings before referring to the forensic examiner's report for more information.

Example #1: *I transported GALE to Villa View Hospital for her sexual assault examination, which was conducted by Registered Nurse Kathy HARPER and assisted by Registered Nurse Daria ZANDI. HARPER saw and documented visible trauma to GALE'S clitoral hood. Additionally, HARPER noticed a hair at 11 o'clock and blood in GALE'S cervix indicating she had started her menstrual cycle. For complete details, see the attached OCJP-923 report prepared by HARPER.*



Cervix with hair on top at 11 o'clock, menstrual blood in os.

Investigator's Follow-Up Documentation

The following samples are then excerpted from an investigator's follow-up report. Again, they document transporting a sexual assault victim to the medical forensic examination, and they summarize the physical findings, this time with a considerable amount of detail. The first example also includes a summary of the results from laboratory analysis, and an indication of how this will guide the next investigative steps.

Example #2: *DONAHUE was transported to Children's Hospital for a SART exam. Doctor Maria GASZA saw and documented an abrasion at the fossa navicularis, which is often seen after forcible penile vaginal intercourse.*

On 3-19-18, I received the results from the lab regarding DONAHUE's SART kit. The lab report indicated semen was found on the cervical swabs, the external genital swabs and the rectal swabs. DNA will be extracted from the evidence and compared to Jose CHAVEZ' reference sample.

Example #3: *On January 25, 2017, at 2355 hours, Officers Borg and Macbeth transported Danner to Villa View Hospital for a sexual assault exam which was conducted by SART Nurse Linda Springstead at 0120 hours, approximately three hours after the assault.*

SART Nurse Springstead saw and documented an abrasion at the 6 o'clock position of the posterior fourchette, red and irritated tissue at the 5 and 7 o'clock positions of the posterior fourchette, red petechiae and spider-like capillaries at the 8 o'clock position of the hymenal fold, and a blood blister-like lesion at the 2 o'clock position of the outer cervix with fresh blood.

Digital photographs were taken and have been retained in the victim's SART record at Villa View Hospital. SART Nurse Springstead impounded Danner's rape kit at Villa View Hospital on Property Tag #769315. For complete details, refer to the OCJP 923 report prepared by Nurse Springstead, which is attached to this follow-up investigation.



Using Couriers to Pick Up Evidence

In the jurisdiction where Example #2 took place, forensic examiners complete property tags for the law enforcement agency, and the property room courier picks up evidence from the hospital every day to transport it to police headquarters where it is impounded. This practice was implemented because it gave forensic examiners more time to complete their packaging and documentation without feeling rushed, and it allowed law enforcement to leave the exam facility with the victim immediately following the examination.

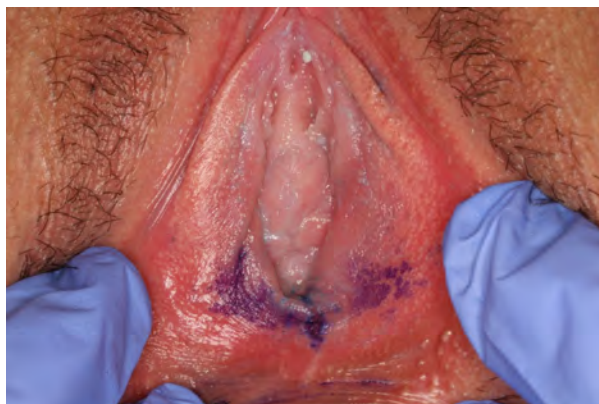This is an example of incorporating a trauma-informed response into daily practice. Victims typically want nothing more at that point than the opportunity to go home and take a long shower or bath. This is also advantageous to the investigation because the responding officer is never involved in the chain of custody, and the shorter the chain of custody, the better. In other words, it is a simple but impactful solution, because the courier was already driving to multiple police substations to pick up evidence that needed to be impounded at headquarters; it simply added another stop to the route already being completed.

Documentation of Injuries and Medical Treatment

In the next two examples, the law enforcement documentation includes detailed descriptions of injuries documented on the victim – both genital and nongenital.

Example #4: *The Victim was transported to St. Luke's Hospital for further investigation and care. Nurse ANITA HALL examined the Victim and completed a rape kit. Victim sustained abrasions on her arms, lower back/rib area and evidence of redness on her neck. Victim was extremely upset and continuously cried during our investigation. Victim was released from the hospital. Victim's sister (CATHY GARCIA) was notified and she transported the Victim home.*

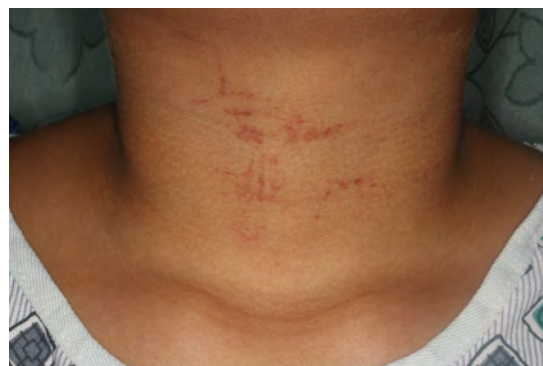Example #5: *Officer YOST arranged for SIMMONS to be taken to Villa View Hospital by paramedic unit #61 (Jeff OLDMAN and Ester MADORA) for a sexual assault exam. The exam was performed by Nurse L. THOMPSON at 2210 hours. Reference External Injuries: Nurse THOMPSON noted SIMMONS' knees were reddened. She had a small cut on the right wrist, a scratch on the left hand (finger) and red abrasions on the right elbow. There were also linear marks on SIMMONS' back which are consistent with the ribbed, non-skid flooring of the bus. A small cut to SIMMONS' upper lip was also noted. A Woods Lamp test for semen was negative.*



Abrasion 7-9 o'clock on right labia minora and 4-6 o'clock on left inner labia minora, both with positive blue dye uptake. Laceration at 6 o'clock on posterior fourchette extending into fossa navicularis with positive blue dye uptake.

Reference Vaginal Injuries: Nurse THOMPSON also noted an abrasion from 7-9 o'clock on the right labia minora and at 4-6 o'clock on the left inner labia minora, both with positive dye uptake. Also, a laceration at 6 o'clock on the posterior fourchette going up into the fossa navicularis with positive blue dye uptake.

Reference Nongenital Injuries: Victim had numerous visible bruises to her neck, and a large bruise to her cheek. For a complete list of victim injuries see OCJP-923, provided by medical staff after SART exam.



Evidence: Medical findings and evidence obtained through the SART exam will be impounded at the Central Division Property Room on tag number 54321. See Officer YOST's preliminary report for further impounds of evidence at Central Division.

Medical Forensic Examination and Evidence

In addition to documenting transportation of the victim to and from the medical forensic examination, and describing the physical findings, the following excerpt provides a

detailed example of the evidentiary items that were collected and impounded by law enforcement. It also notes that the victim was provided with the informational form explaining victims' rights, as required by law in the state of California.

Example #6: *Once JACKSON was finished speaking with the emergency room doctor at UCSD, I transported her to University Community Medical Center (UCMC) 5550 University Avenue for a SART examination. I met with SART Nurse Marta MCDONALD RN #3790 and briefed her on this case. MCDONALD informed me that a SART advocate had already been called and was en route to assist the Victim.*

After the forensic examination was concluded, I collected the SART forensic evidence kit from Nurse MCDONALD and impounded it in the property room at Headquarters, Property tag #905611, with a hazardous materials label and instructions for the kit to be refrigerated.

All the clothing evidence, also collected by Nurse MCDONALD was placed in separate paper bags to prevent cross contamination and all were impounded on Property tag #905612 at Headquarters.

EVIDENCE:

- 1: Light blue underwear. Impounded at Headquarters*
- 2: Pink bra, Impounded at Headquarters*
- 3: Tan cloth pants. Impounded at Headquarters*
- 4: White cloth socks. Impounded at Headquarters*
- 5: Brown cloth sweater. Impounded at Headquarters*
- 6: Blue spandex flowered shirt. Impounded at Headquarters*

I remained at the SART office until JACKSON was finished with her examination. I transported her back to her vehicle at UCSD Medical Center. I provided JACKSON with a copy of our Department's form for Victims of Domestic Violence and Sexual Assault as well as our case number and phone number to our Sex Crimes Unit.

INJURIES: *JACKSON complained of slight pain to her anus and the surrounding area. She explained it was sore to the touch. Nurse MCDONALD informed me that she found no visible physical trauma to JACKSON'S vaginal area; however, there was a slight pinhole size tear inside her anus. See MCDONALD's SART exam report for complete details.*

Examination of an Adult with an Intellectual Disability

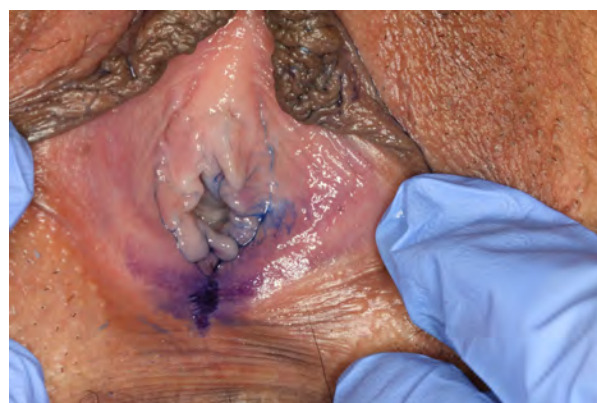The final excerpt provides additional details needed to document the forensic interview and medical forensic examination of an adult with an intellectual disability. Other aspects of the documentation are similar to the examples provided so far.

Example #7: *On July 16, 2018, at 0830 hours, I transported Gomez and her mother to the Center for Child Protection at Children's Hospital. Although Gomez is an adult, she has a moderate to severe intellectual disability. Therefore, I requested an interview by a trained forensic interviewer. At approximately 0900 hours, LCSW Blanca Arias conducted a videotaped forensic interview with the victim concerning this incident. I witnessed the interview, which was conducted in Spanish.*

Although the history obtained by LCSW Arias was more detailed than what I had obtained earlier, Gomez's story was consistent with what I had learned. For further information, a copy of the video record was impounded as evidence and Arias' written report concerning this interview is submitted with this follow-up report.

Immediately following the forensic interview, Dr. Marilyn Kaufhold examined Gomez. Dr. Kaufhold saw and documented a laceration on the posterior fourchette at 6 o'clock and hymenal bruising, which is frequently seen following forced vaginal penetration. It is Dr. Kaufhold's conclusion that these physical findings are consistent with the history given by the victim.

Digital photographs were taken and will be retained with the victim's records at the Center for Child Protection. For further information, a copy of Dr. Kaufhold's OCJP 925 report is submitted with this follow-up report.



Laceration at 6 o'clock on the posterior fourchette going up into the fossa navicularis. Positive blue dye uptake.

Which Evidence is Likely to be Most Probative?

We have stressed how critical it is that evidence be viewed in context, rather than disjointed or unrelated parts. This is one reason why the findings from a forensic examination of a victim or suspect must be incorporated into law enforcement documentation, not just documented in the report completed by the forensic examiner.

A similarly holistic approach is needed to answer the question, "Which evidence is most likely to be probative in this case?" This determination requires investigators to thoroughly review *all* the evidence collected in a case – including evidentiary samples and documentation of physical findings such as injuries during a victim and suspect examination, crime scene evidence, and statements from victims, suspects, and witnesses, along with any other evidence or information gathered – and then carefully evaluate this evidence in the context of the history of the sexual assault.

As part of this review, investigators need to consider:

- What are the potential investigative purposes of each piece of evidence?

- What is known about the case when all the pieces of evidence are put together?

The answers to these questions can guide an investigator's decisions about which evidentiary samples and items to prioritize for laboratory analysis, and what additional evidence and information to seek, as well as how to make decisions regarding investigative strategies and conclusions. Perhaps the best way to illustrate this point is to practice using a variety of case studies.

Practical Application: Case Study Analyses

Several case studies will be used to apply the knowledge gained so far in this module. For each one, we offer a case synopsis, followed by the additional investigative steps taken, and the evidence and information gathered. You will be asked to evaluate each case from the perspective of a law enforcement investigator. First, you will be asked to answer a series of questions to help evaluate the assault history and other case facts. Ultimately, you will need to make determinations regarding which evidence is most likely to be probative. In this document, the answers are not provided to questions or exercises. However, they are available in the online version of the module in the OLTl.

These case studies build on each other, to apply what is learned in scenarios of gradually increasing complexity. The case scenarios include the following:

1. Forcible rape of a 16-year-old female by a 28-year-old male soccer coach.
2. Forcible rape, digital penetration, and oral copulation of a female by two male suspects.
3. Suspected drug-facilitated sexual assault of a female by one or more male fraternity members.
4. Forcible rape and sodomy by a male suspect who met a female victim at a party and offered her a ride home.
5. Attempted sexual assault of a female by a male stranger in a park.
6. Forcible oral copulation of 22-year-old male victim by a male acquaintance.

In the case studies, the names of the victim, suspect, and other associated parties have been changed, but the names of some responding professionals have been retained.



Wording for Case Studies

Please note that the case study materials are drawn from actual reports, but they were adapted for the purpose of this exercise. For example, each case study begins with a synopsis summarizing the facts of the case; as such, they do not always include direct quotes to document exactly what the victim said during an

interview. However, direct quotes should be used both by forensic examiners and investigators to document verbatim statements made by victims and suspects in their reports. For guidance on how investigators and forensic examiners should document victim, witness and suspect statements in their reports, please see the OLT module on [Effective Report Writing: Using the Language of Non-Consensual Sex](#).

Case Study #1: Forcible Rape of a 16-Year-Old Female by a 28-Year-Old Male Soccer Coach

Synopsis

On Tuesday, August 18, 2015, the parents of 16-year old Jackie Thomas called police communications at 1430 hours to report that their daughter had been sexually assaulted on August 14, 2015, at approximately 2100 hours. Communications dispatched Officer Davis to meet Thomas and her parents at their home to evaluate a report of rape. With Thomas' and her parents' consent, Officer Davis interviewed Thomas in private to obtain a preliminary statement.

Thomas said she was sexually assaulted by a 28-year old man she knows as Jim. Jim lives in the neighborhood and coaches soccer. Thomas described how Jim forced his penis into her vagina after she told him to stop. She said she believes Jim ejaculated, and she thought he might have used a condom. When Thomas returned home later that night, she immediately showered "for a very long time" before putting on her sweats and going to bed. She also showered at least three more times before talking to her parents.

Thomas said at first they were just talking and watching a movie, but then Jim sexually assaulted her on his living room couch. Thomas said she told Jim to stop, but he didn't. Jim told Thomas not to tell anyone what happened, or "she would get in trouble." Thomas said she had never been to Jim's home before, but he invited her over to talk about how she could improve her soccer game.

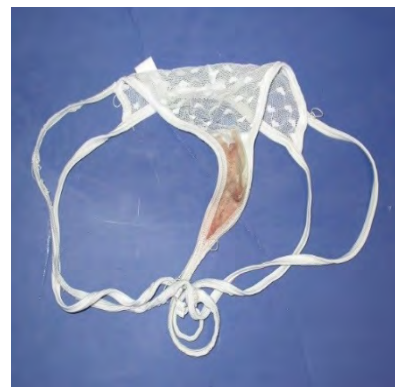Thomas believes Jim is married, but no one else was home at the time of the sexual assault. She said Jim had never been inappropriate before, and she had never been sexually active with anyone. Thomas had trouble sleeping and eating following the sexual assault, so she decided to tell her parents what happened around 1145 hours on Tuesday morning, August 18, 2015. After talking and considering their options, Thomas' parents called the police to report the assault.

After concluding the preliminary interview, Officer Davis facilitated a medical forensic examination at Eisenhower Valley Women's Institute.

Medical Forensic Examination of the Victim

Officer Davis, Thomas, and her parents arrived at the medical facility at 1530 hours. A rape crisis center advocate was at the facility when they arrived. Thomas agreed to allow the advocate to accompany her through the examination. While Thomas spoke with the advocate, the officer briefed the SANE with the information he obtained during the preliminary interview (the synopsis above).

As the SANE began the examination, she collected the underwear the victim was wearing. Following standard protocol, the SANE then collected a variety of swabs from in and on Thomas' body, including external genital and internal vaginal and cervical swabs. The SANE also collected swabs from inside Thomas' mouth as well as the external area around her mouth (but not the lips).



Oral Swabbing Techniques

External swabs can often recover more foreign biological material from the skin surrounding the mouth than the oral swabs taken from inside the mouth. When swabbing the areas around the victim's mouth, the lips are not swabbed. This is because they will produce too much of the victim's DNA, which could potentially mask the smaller quantity of foreign DNA that might be recovered.

Fingernail scrapings/swabbings were also collected from Thomas, as well as body surface swabs of her neck, breasts, and thighs. Care was taken to swab the area of Thomas' left upper chest where a suck mark was documented. Blood and urine samples were also collected, in case toxicology testing was later needed, depending on the course of the investigation.

Exam Findings

The SANE stated that the visible findings were consistent with the victim's history that she had not been sexually active as well as the time frame she described. These findings were documented by the SANE as follows:

- *Laceration from 5-6 o'clock on the posterior fourchette, positive blue dye uptake, with complaint of soreness at that location. Pulls away when touched there.*
- *Abrasion at 5-7 o'clock on the fossa navicularis, with positive blue dye uptake, complains of soreness when touched there.*
- *Purple/blue bruise at 9 o'clock on the hymen. Hymen is swollen.*
- *Purple/blue bruise/suck mark on left upper chest.*

The [Medical Forensic Examination Report for Case Study 1](#) demonstrates how the SANE documented the findings from this examination, including observable physical findings, statements made by the patient, and the examiner's conclusions.



Understanding Exam Findings

Note that the posterior fourchette, fossa navicularis, and hymen are external genital structures. Positive blue dye uptake is consistent with an injury after toluidine blue dye is applied to the area of the suspected injury.

Post-Exam Briefing

Following the examination, the SANE briefed the officer, comparing what the officer told her prior to the examination and what she learned during the examination. The SANE said the victim told her the suspect was drinking beer when she arrived. He also offered her a beer, which she took. The victim said she didn't finish the whole beer. She did not feel intoxicated or incapacitated in any way. She said she hadn't mentioned the beer to her parents or Officer Davis because she didn't think it was a big deal.

The SANE advised Officer Davis that the clothing the victim was wearing at the time of the sexual assault was still in her laundry basket in her bedroom. Also, in the laundry basket was a pair of sweat pants the victim put on immediately after showering (she did not put on underwear after showering).

The victim said she wasn't sure if the suspect wore a condom during the sexual assault, but she heard what she thought was a wrapper being opened. She never actually saw a condom, new or used, at any time. The victim said that she used a Kleenex to clean herself afterwards because she was bleeding. She said she discarded the Kleenex in the suspect's bathroom waste basket.

Next Investigative Steps

Following the post-exam briefing, Officer Davis called to consult with the Sex Crimes duty detective. Detective Hershman and Officer Davis spoke about the next steps to take.



Please describe 3 investigative steps the officer and detective should consider taking immediately, based on the information gathered so far in this case.

- 1.
- 2.
- 3.

Collecting Victim Clothing

One critical step for the reporting officer was to return to Thomas' home and obtain the pertinent clothing items from her laundry basket. Officer Davis gathered the clothing, and then impounded each item in a separate paper bag, clearly indicating the items that were worn at the time of the assault (and put back on immediately afterward to wear home), versus the sweat pants and t-shirt the victim put on after showering.



Importance of Communication

This example highlights the importance of communication between the forensic examiner, the reporting officer, and any responding detectives. Victims often wear clothing to the examination that is not likely to yield probative biological material. In fact, they may have changed clothing several times since the sexual assault. Therefore, it is important to find out whether any clothing or other crime scene evidence needs to be collected from other locations.

When asked, a victim might indicate that the clothing worn at the time of the assault is now on a bedroom floor, in a laundry basket, or somewhere else. Victims also frequently dress quickly after being sexually assaulted, and they may leave an item of clothing or other item at the location of the sexual assault. These items are also important to collect, both for potential biological evidence but also to place the victim at the assault location.

Law Enforcement Documentation of Exam Findings

At this point, we would like you to practice documenting the medical forensic exam and exam findings in a law enforcement report. Please look back at the synopsis and the other case study materials (e.g., the victim's medical forensic examination report), and document the police response, including a synopsis of the type of sexual assault reported, the length of time between the assault and the medical forensic exam, and the exam findings from this first case study. If needed, you can refer to the section on [Law Enforcement Documentation of Exam Findings](#) for help.



Please synopsise the assault history, key details, and the exam findings. A synopsis covers the elements of the criminal offense(s) being reported and the basic facts of the case. It serves as the introduction to an investigator's case.

Suspect Contact

This case was assigned to Detective Hershman on Wednesday, August 19, 2015, and he contacted the victim to schedule a detailed follow-up interview later the same day. After interviewing the victim and evaluating the information in this case, Detective



Hershman decided to contact the suspect, Jim Flowers, as soon as possible. Detective Hershman went to the home of Jim Flowers on August 20, 2015, the next day. Upon initial contact, the detective advised Flowers that he was not under arrest and that he could tell the detective to leave at any time. Flowers invited the detective in and agreed to talk to him. The detective then asked the suspect to tell him what happened last Friday evening, August 14, 2015.

The suspect said the victim came to his house, but the two did not have any sexual contact at that time or any other time. He said he only invited her to come over because she asked him to help her with her soccer game.

Following the suspect's statement that he did not have any sexual contact with the victim, the detective obtained a telephonic search warrant to search the suspect's home and obtain a DNA reference standard from the suspect. The search and collection of the reference standard were conducted in accordance with state laws and police department policies and procedures.

When the search warrant was executed, the investigator learned that the suspect's bathroom waste basket had been emptied and the weekly trash had already been removed by the sanitation company. No condoms or condom wrappers were found.

A crime scene technician responded to assist the detective with the search warrant. The technician screened the living room couch and the surrounding carpet with an alternate light source to determine whether any of the victim's biological material could be located (such as epithelial cells or blood), but the results were inconclusive. As a result, the detective had the three cushions from the couch removed and impounded for further analysis by the crime laboratory.

Investigator Assessment

We now offer a series of questions designed to guide your assessment of the evidence from the perspective of a law enforcement investigator.



Is the victim able to provide a narrative account of events?

No Yes Unknown

Is there a starting point for the investigation regarding the number of suspects, the identity of the suspect(s), and the specific sexual acts committed?

No Yes Unknown

Could the victim's age or the lack of sexual experience impact her account?

No Yes Unknown

How much time elapsed between the sexual assault and the victim's exam?

- Less than 1 day (up to 24 hours) 1-2 days (25-48 hours)
 3-5 days (49-120 hours) More than 5 days (beyond 120 hours)

Did the SANE collect the victim's clothing at the time of the victim's exam?

- No Yes Unknown

Why or why not? Please explain.

Did the SANE provide Officer Davis with important information about where additional evidence might be located? If so, was that evidence located and collected?

- No Yes Unknown

What other information did the SANE provide the reporting officer that is time-sensitive? Please explain.

Is there any indication (so far) that toxicological analysis will be needed in this case?

- No Yes Unknown

Is there any indication (so far) that reference samples need to be collected from a prior consensual sexual partner?

- No Yes Unknown

How much time elapsed between the sexual assault and the detective's initial contact with the suspect?

- Less than 1 day (up to 24 hours) 1-2 days (25-48 hours)
 3-5 days (49-120 hours) More than 5 days (beyond 120 hours)

Why do you think the detective only collected a buccal swab rather than requesting a suspect examination to collect forensic evidence? Please explain.

Prioritizing Items for Analysis

Based on the information provided so far, an investigator can evaluate the assault history and available evidence, to prepare a request for laboratory analysis of evidentiary samples and other items. Because of the increasing demand for laboratory services, it is important for law enforcement to work as efficiently as possible and prioritize laboratory requests for analysis based on all the information and evidence available in a case. This prioritization will help investigators and criminalists determine which items are most likely to yield probative evidence, which can significantly improve case outcomes.

To practice this type of decision making, we would like you to evaluate the evidence collected in this case to determine the possible priorities for laboratory analysis. Please keep in mind that there is no single “right answer” to this task. However, we have provided the type of information you will want to consider as you make these determinations.

Please note: In some instances, you might group together a limited number of items for analysis. For example, you might group the internal vaginal and anal swabs together, or the penile and scrotal swabs. However, it is best to consider each item individually, because your task is to critically evaluate and prioritize available evidence in terms of its potential for advancing the investigation. In addition, you will need to consider each item of clothing based on the victim’s statement and the medical forensic examination to help prioritize which clothing evidence should be examined by a criminalist.



Please select 3-5 items from the following lists and rank them from highest (1) to lowest order of priority.

Victim Clothing

- Shirt (worn at the time of the assault)
- Shorts (worn at the time of the assault)
- Bra (worn at the time of the assault)
- Underwear (worn at the time of the assault)
- Sweat pants (put on after showering)
- T-shirt (put on after showering)
- Underwear (worn to the examination)

Medical Forensic Examination

- External peri-oral swabs taken from around the mouth (not the lips)
- Oral swabs from inside the mouth
- Fingernail scrapings/swabbings
- Body surface swabs (such as neck, breasts, thighs)
- External genital swabs
- Internal vaginal/cervical swabs
- External anal swabs



_____ Internal rectal swabs

Crime Scene Evidence

_____ Couch cushions

Please describe the rationale for your rankings:

Laboratory Findings

Returning to the case study, the investigator submitted evidence to the laboratory for analysis, and semen was found on the underwear the victim was wearing at the time of the sexual assault. DNA testing then matched the profile to the suspect's DNA reference standard. This result could serve a variety of purposes in terms of this investigation.



Below we provide a variety of purposes that could potentially be met with this laboratory result. Please mark the purposes that can be met, based on the information provided so far.

- Establish sexual contact
- Establish penile-vaginal penetration
- Include suspect
- Exclude suspect
- Link cases based on any DNA profiles developed
- Corroborate the victim's statements
- Challenge the victim's statements
- Corroborate the suspect's statements
- Challenge the suspect's statements

Testing Process

In general, laboratory analysis should proceed in a step-by-step fashion with each item prioritized based on the victim's statement, forensic exams of the victim and/or suspect, and other information developed during the investigation. If the results from the first item establish the suspect's identification and the elements that need to be proven in a case, analysis might stop at that point. If not, additional items might be submitted for analysis. To assist in this process, we offer a [Sexual Assault Case History and Analysis form](#). This one is filled out with information drawn from the first case study.





Based on the information provided in this case study, do you believe it would be prosecuted in your jurisdiction? Why or why not?

Would you also consider charging the suspect with statutory rape? Why, or why not?



Appendix F includes the [Medical Forensic Report for Case Study #1](#), and the [Sexual Assault Case History and Analysis](#) form completed for this case study. Appendix G provides blank versions of all the forms used in the case studies.

Case Study #2: Forcible Rape, Digital Penetration, and Oral Copulation of a Female by Two Male Suspects

Synopsis

On May 3, 2015, at around 2030 hours, 19-year old Cassi Jackson called 911 to report that she was just raped. She said she went to visit her boyfriend at around 1800 hours, but he wasn't home. Instead, two of his friends, Tyrone Crosby and Max Verduzco, were there, and they invited her in to watch TV. They watched TV for a while, but then the two suspects demanded sex from Jackson. When she refused, they forcefully carried her into the bedroom where they took turns raping her vaginally on top of the bed. Jackson said she believes both suspects wore a condom during the sexual assault, and she believes they both ejaculated.

Jackson estimated that the assault took place between 1930 and 2000 hours. Afterward, she "threw on her clothes," and went home as fast as she could. After calling 911, Deputy Cathy Garcia responded to Jackson's home where she conducted a preliminary interview and obtained an initial statement. Deputy Garcia determined that Jackson was still wearing the clothing she had on at the time of the assault.

The victim and Deputy Garcia tried to call Jackson's boyfriend, Jerald Ferguson, but he didn't answer his cell phone. Jackson gave Deputy Garcia Ferguson's cell phone number and his address. Deputy Garcia then spoke to her sergeant who dispatched another Deputy to Ferguson's home, but no one answered the door. Deputy Garcia transported Jackson to Eisenhower Valley Women's Institute at 2100 hours for a medical forensic examination. Deputy Garcia briefed SANE Diana Faugno with the information she had obtained so far.



Swabs Collected During the Examination

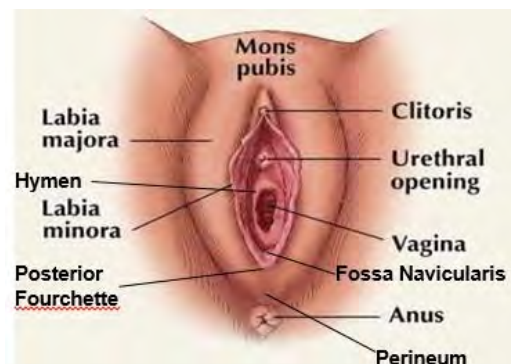
Following the exam facility's standard protocol, the SANE collected a variety of swabs from in and on the victim's body:

- External peri-oral swabs taken from around the mouth (not the lips)
- Oral swabs from inside the mouth
- Fingernail scrapings/swabbings
- Body surface swabs (such as neck, breasts, thighs)
- External genital swabs
- Internal vaginal/cervical swabs
- External anal swabs
- Internal rectal swabs

Exam Physical Findings

In the [Medical Forensic Report for Case Study #2](#), the SANE summarized the following visible physical findings from the examination:

- *4-8 o'clock on the fossa navicularis is reddened and abraded. There is positive blue dye uptake and she complains of tenderness when touched there and pulls away.*
- *Hymen has a red bruise at 3 'clock.*
- *Suck mark to middle of neck.*
- *Positive alternative light source (ALS) finding to left groin with 5x6 cm blue/black bruise. Pulls away when touched there.*
- *Redness around wrists. Complains of pain there.*



Faugno also described the subjective indicators of injury or pain in her forensic report. When the victim was asked whether she was experiencing any anal-genital pain or injury, she responded: "I am sore down there." When asked about nongenital pain or injury, she said, "My stomach hurts." Then later, when Faugno noted redness to the victim's wrists, the victim said, "It hurts there now." Faugno concluded that the examination findings were consistent with the history provided by the victim. Faugno also took numerous photographs, including the bruise on the victim's thigh.

Clothing Collected During the Exam

The SANE collected the victim's clothing that she was wearing at the time of the assault and wore to the hospital (pants, shirt, bra, and underwear). Prior to packaging the clothing, Faugno examined the clothing for signs of force, such as stretching, tearing, and missing buttons; her observations were noted in the [Clothing Documentation form completed by Forensic Examiners](#). Specifically, Faugno noted that the victim's bra strap was torn, her underpants had a "stained crotch," her shirt was missing a top button, and the zipper on her pants was down (the zipper was described as unremarkable).

The victim also wore sandals to the examination, but these were not collected because the SANE determined (based on the assault history) that they were not likely to contain probative evidence and the victim didn't want to give them up.

Post-Exam Consultation

Following the examination, the SANE summarized her findings and advised Deputy Garcia that in addition to penile-vaginal rape, the victim stated that the suspect who was identified as Tyrone also forced her to orally copulate his penis. The suspect identified as Max also forced his fingers in the victim's vagina.

Deputy Garcia asked Faugno whether the victim had any recent consensual sex, to determine whether DNA reference standards might be needed from a consensual partner. The SANE relayed that the victim said she and her boyfriend had sex two days before the assault, and a condom was not used.

Investigator Assessment

With this information, we now offer a series of questions designed to guide your assessment of the evidence from the perspective of a law enforcement investigator.



Is the victim able to provide a narrative account of events?

No Yes Unknown

Is there a starting point for the investigation regarding the number of suspects, the identity of the suspect(s), and the specific sexual acts committed?

No Yes Unknown

Did the deputy and the SANE brief before and after the victim's medical forensic examination?

No Yes Unknown

Did the SANE learn anything about the type of sexual assault offenses the suspects committed that the deputy did not know prior to the exam? If so, what?



How much time elapsed between the sexual assault and the victim's medical forensic examination?

- Less than 5 hours 5-24 hours (1 day)
 1-2 days (25-48 hours) 3-5 days (49-120 hours)
 More than 5 days (beyond 120 hours)

Did the SANE document any nongenital injuries to the victim's body? If so, please describe them.

Did the SANE document any other findings that would indicate another possible source of probative evidence? If so, please explain.

Is there any indication (so far) that toxicological analysis will be needed in this case?

- No Yes Unknown

Is a reference standard needed from the victim's boyfriend to exclude his DNA profile?

- No Yes Unknown

Continuing Investigation

Detective Debbie Deloach, the on-call detective, responded to assist Deputy Garcia. The victim contacted her boyfriend, Jerald Ferguson, by phone and he agreed to meet with Deputy Garcia and Detective Deloach at approximately 0130 hours. Ferguson advised Deputy Garcia that Tyrone's last name is Crosby and Max's last name is Verduzco, but he wasn't sure of either of their home addresses. Ferguson said he didn't understand why his two friends would sexually assault his girlfriend. He then gave consent to search his house.

Deputy Garcia completed a crime scene diagram and took photographs of the bedroom where the sexual assault took place. Deputy Garcia didn't see any visible signs of a struggle or evidence on the bed or in the bedroom. No condoms or packaging were found. The comforter from the top of the bed where the assault occurred was collected and impounded.

After explaining the importance of a reference standard to exclude his DNA profile, the victim's boyfriend voluntarily agreed to provide Detective Deloach with a buccal swab. Detective Deloach thanked Ferguson for his cooperation and advised the victim of the next investigative steps. She explained that she would contact the victim within the next couple of days to schedule a follow-up interview, after the victim had a chance to rest.

Detective Deloach then returned to the station to conduct computer research to identify both suspects, as well as their last known home addresses. Once identified, a criminal history check revealed that Max Verduzco had numerous prior drug-related arrests and Tyrone Crosby had a previous arrest for sexual assault. Detective Deloach also obtained search warrants for complete forensic examinations of both suspects.

Suspect Exams

Later that morning, Detective Deloach, with assistance from patrol, arrested both suspects at their homes. Deloach advised both suspects of their Miranda rights. Verduzco said Cassi came to the house knowing they were there, and her boyfriend was gone, because she wanted to "score some heroin." He said all three "got high" together and then they had consensual sex (a "threesome"). Verduzco said he and Tyrone both wore condoms. Crosby did not make a statement, stating that he wanted a lawyer.

The two suspects were transported in separate patrol cars to Eisenhower Valley Institute for complete forensic examinations, conducted by different SANEs.

The forensic examination of Tyrone Crosby yielded the following evidentiary samples:

- External peri-oral swabs taken from around the mouth (not the lips)
- Oral swabs from inside the mouth
- Buccal swabs
- Fingernail scrapings/swabbings
- Body surface swabs (as indicated by history)
- Swabs from the penile shaft
- Swabs from the scrotum
- Swabs from the perineum
- Foreign material
- Dried secretions
- External anal swabs
- Internal rectal swabs

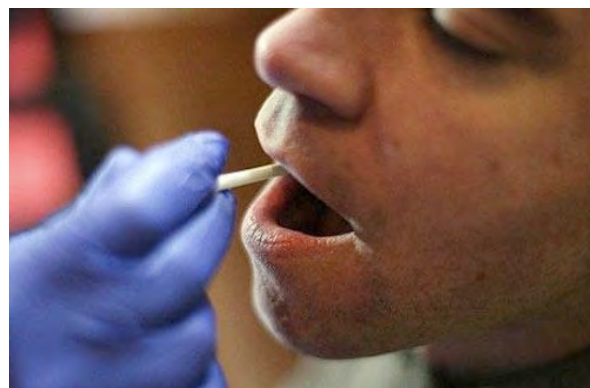

Photo Credit: Ted Bauer

The forensic examination of Max Verduzco yielded the following evidentiary samples:

- External peri-oral swabs taken from around the mouth (not the lips)
- Oral swabs from inside the mouth
- Buccal swabs (as indicated by history)
- Fingernail scrapings/swabbings
- Body surface swabs
- Swabs from the penile shaft
- Swabs from the scrotum
- Swabs from the perineum
- Foreign material
- Dried secretions
- External anal swabs
- Internal rectal swabs

Following each exam, the SANE completed Suspect Examination Documentation forms for [Max Verduzco](#) and [Tyrone Crosby](#).

Investigator Assessment of Suspects' Forensic Examinations

We now offer a series of questions designed to guide your assessment of the evidence from the perspective of a law enforcement investigator.



Forensic Exam of Max Verduzco

How much time elapsed between the sexual assault and the detective's initial contact with Max Verduzco?

- Less than 1 day (up to 24 hours) 1-2 days (25-48 hours)
 3-5 days (49-120 hours) More than 5 days (beyond 120 hours)

Did the SANE document any visible genital or nongenital injuries to Verduzco's body?

- No Yes Unknown

How might the evidentiary samples collected and documented during Verduzco's examination advance the investigation in this case study?





Forensic Exam of Tyrone Crosby

How much time elapsed between the sexual assault and the detective's initial contact with Tyrone Crosby?

- Less than 1 day (up to 24 hours) 1-2 days (25-48 hours)
 3-5 days (49-120 hours) More than 5 days (beyond 120 hours)

Did the SANE document any visible genital or nongenital injuries to Crosby's body?

- No Yes Unknown

How might the evidentiary samples collected and documented during Crosby's examination advance the investigation in this case study?

Suspect Statements

When advised of his Miranda rights by Detective Deloach, Max Verduzco waived his rights and Tyrone Crosby invoked his right to remain silent. Remember that even if a suspect invokes their right to remain silent, any spontaneous statements made to a SANE or the investigator during a forensic examination should always be documented by the investigator and/or the SANE.



Statements by Max Verduzco

Please review [Max Verduzco's](#) forensic exam report to determine whether any statements were made during the exam. If any such statements were made, please document those statements in direct quotes below:



Statements by Tyrone Crosby

Please review [Tyrone Crosby's](#) forensic exam report to determine whether any statements were made during the exam. If any such statements were made, please document those statements in direct quotes below:

Follow-Up Interview with Victim

Detective Deloach scheduled a follow-up interview with the victim two days later. During the interview, she asked Jackson whether she bought any drugs from either suspect, and if any of them took any drugs at the time of the assault. Deloach clarified that she was asking this question because one of the suspects raised the issue, and she wanted to make sure she had all the correct information. The detective assured the victim she was not concerned about any illegal drug use on the victim's part, and she was not interested in making an arrest for any such issues. The investigator said her primary concern is investigating the sexual assault, and that it is critical that Jackson is truthful about everything that happened.

The victim said she did not take any drugs at the time of the assault; she said they were lying about her coming to the house to buy or do drugs. She said nobody even had any alcohol. She said she absolutely did not want to have sex with either suspect, and she became very upset in the interview. Detective Deloach asked Jackson if she wanted to take a break or talk in private with the victim advocate who was accompanying her, but the victim said she just wanted to finish the interview. Following the interview, Detective Deloach took photographs of the evolving bruises on the victim's wrists and thigh.

Synopsis of the Investigation

Once again, we would like you to practice incorporating a synopsis of the assault history with the probable defense, any criminal history of the suspects, the impact of the exam findings, and any other key details that would be documented in an investigator's follow-up report. This will help to evaluate how exam findings and the analysis of other evidence might advance the investigation and potential charges.



Please write a synopsis for the investigator's follow-up report. Remember, a synopsis covers the elements of the criminal offense(s) being reported and the basic facts of the case. It serves as the introduction to an investigator's case file.

Prioritizing Items for Laboratory Analysis

Based on the information provided so far, the detective can evaluate the assault history and available evidence to prepare a request for laboratory analysis. Once again, we would like you to evaluate the items collected in this case to determine their priority for laboratory analysis. Remember, there is no single "right answer," but we have provided the type of information you will want to consider as you make these determinations.



The evidentiary items have been grouped in four categories: (1) Medical forensic examination of the victim, (2) Victim clothing, (3) Tyrone Crosby's forensic examination, and (4) Max Verduzco's forensic examination. Please select 3-5 items from the following lists and rank them from highest (1) to lowest order of priority. Use the space below to describe the items and their ranking. Not all items will be included in the ranking.

Medical Forensic Examination of the Victim

- External peri-oral swabs taken from around the mouth (not the lips)
- Oral swabs from inside the mouth
- Fingernail scrapings/swabbings
- Body surface swabs (such as neck, breasts, thighs)
- External genital swabs
- Internal vaginal/cervical swabs
- External anal swabs
- Internal rectal swabs

Victim Clothing (worn at the time of the assault, and to the examination)

- Shirt
- Shorts
- Bra
- Underwear

Forensic Examination of Tyrone Crosby

- External peri-oral swabs taken from around the mouth (not the lips)
- Oral swabs from inside the mouth
- Buccal swabs
- Fingernail scrapings/swabbings
- Body surface swabs (as indicated by history)
- Swabs from the penile shaft
- Swabs from the scrotum
- Swabs from the perineum
- Foreign material
- Dried secretions
- External anal swabs
- Internal rectal swabs

Forensic Examination of Max Verduzco

- External peri-oral swabs taken from around the mouth (not the lips)
- Oral swabs from inside the mouth
- Buccal swabs (as indicated by history)
- Fingernail scrapings/swabbings
- Body surface swabs
- Swabs from the penile shaft
- Swabs from the scrotum
- Swabs from the perineum
- Foreign material
- Dried secretions
- External anal swabs
- Internal rectal swabs

Please describe the rationale for your rankings:

To see how the detective evaluated the information and evidence available in this case, please see the [Sexual Assault Case History and Analysis](#) for Case Study #2.

Laboratory Findings

In the jurisdiction where this case study takes place, the laboratory routinely analyzes all swabs in the evidence kit from the victim's examination. However, no foreign biological material was detected on the evidence submitted in this case.

On the other hand, the penile/scrotal swabs from both suspects showed the presence of semen as well as epithelial cells, indicating recent sexual activity. DNA analysis of the semen indicated that each suspect had his own semen on his penile/scrotal swab. More important, DNA analysis of the non-sperm fraction (the epithelial cells) from the penile/scrotal swabs of both suspects indicated that they came from the victim.

The fingernail swabs taken from Verduzco also showed the presence of the victim's epithelial cells.



Below we provide a variety of purposes that could potentially be met with these laboratory results. Please mark the purposes that can already be met, based on the information provided so far.

- Establish sexual contact
- Establish oral copulation
- Establish digital penetration
- Establish penile-vaginal penetration
- Include suspect(s)
- Exclude suspect(s)
- Link local cases based on DNA developed from forensic evidence
- Corroborate the victim's statements
- Challenge the victim's statements
- Corroborate the suspect's statements
- Challenge the suspect's statements

Investigator's Conclusion

Based on the information provided in this case study, we would like you to practice summarizing the facts of the case in a conclusion written by the investigation. This will include the laboratory findings and any findings from the medical forensic examination, as well as other key details and evidence, and a listing of the charges requested.





Please write a conclusion from the perspective of the investigator in the case.

Overcoming a Consent Defense

Because the suspects in this case stated that the victim consented to the sexual acts, the DNA results do not specifically address this defense. When the consent defense is raised, however, suspects will often try to undermine the credibility of the victim. In this case, one of the suspects made statements about the victim's drug use. Toxicological analysis could therefore be used to potentially corroborate or challenge this statement.

Rather, a consent defense is challenged with evidence that helps to establish that force, threat, or fear were used to perpetrate the sexual assault. In this case, this includes injuries documented during the victim's examination (redness on the victim's wrists and bruising on her thigh). In addition, clothing can be examined for signs of force (such as stretching, tearing, missing buttons). In this case the SANE documented a torn bra strap, stained underwear, and the fact that the victim's blouse was missing a top button. In this case, the investigator should ask the victim if the button had been missing before the assault or if it was a result of any force used.

Evidence of force, threat, or fear might also be found in the specific case facts (the presence of two suspects, size differentials, isolation etc.). However, a consent defense is also challenged when a suspect's DNA profile links with a prior arrest or conviction for a similar type of crime – or when it matches with forensic evidence in one or more additional sexual assault cases. In this case, it will be important for the investigator to obtain information about Crosby's prior arrest for a sex offense, including a copy of the crime report whenever possible. This report could be used to establish "prior bad acts" and challenge the credibility of the suspect's statement regarding the victim's consent.



Appendix E includes an [investigator's follow-up report for a drug-facilitated sexual assault](#), a [stranger sexual assault](#) and a [template for an investigator's follow-up report](#) that illustrate what a comprehensive follow-up investigation might look like.



Based on the information provided in this case study, do you believe it would be prosecuted in your jurisdiction? Why or why not?



Appendix F includes: the [Medical Forensic Report for Case Study #2](#), the [Clothing Documentation by Forensic Examiners](#) completed by the SANE, the



[Sexual Assault Case History and Analysis](#) completed by the detective, and the Suspect Exam Documentation reports for [Max Verduzco](#) and [Tyrone Crosby](#).

Case Study #3. Suspected Drug-Facilitated Sexual Assault of a Female by One or More Male Fraternity Members

Synopsis

On January 9, 2015, Isabella Sandoval, a 20-year-old college student, attended a fraternity party where she consumed so much alcohol that she passed out in one of the bedrooms. The following morning, January 10th, at about 1100 hours, she woke up in her own bed, nude, experiencing vaginal discomfort. Sandoval found her clothes on the floor at the foot of her bed. She has no recollection of the events of the night before, beyond a certain point when she became extremely intoxicated. Although Sandoval went to the party with friends, she has no idea what happened to her friends or how she got from the bedroom at the fraternity party to her own bedroom. When Sandoval awoke, she got dressed and then called her friends, who said they left the party at midnight. Before they left, they checked with Sandoval who told them she wanted to stay at the party because she was having a good time. Sandoval believed she might have been sexually assaulted, so she decided to call the police at approximately 1130 hours.

Deputy Hafner responded to Sandoval's home at approximately 1330 hours. Sandoval said she smokes marijuana on occasion, but she did not do any drugs at the fraternity party. Based on the limited information available, it was determined that Sandoval might have been assaulted between approximately midnight on January 9th, and 0100 hours on January 10, 2015.

After obtaining Sandoval's preliminary statement, Deputy Hafner examined her bedding, but didn't see any obvious signs of a struggle or sexual assault (e.g., blood or stains). Deputy Hafner collected the bedding as well as Sandoval's clothing at the foot of the bed that she had worn to the fraternity party: a pair of underwear, a skirt, and a blouse.

Prior to impounding this evidence, Deputy Hafner used a [Clothing Documentation Form for Law Enforcement](#) to document that he photographed and examined the condition of the clothing. In particular, he photographed the victim's underwear that she wore to the party and noted that there was an unknown stain on the blouse, possibly vomit.

Deputy Hafner also checked the victim's room and bathroom for any items that might have been used to clean up following sexual activity, as well as any condoms or wrappers, but did not find anything. Deputy Hafner then drove Sandoval to Eisenhower Valley Women's Institute for a medical forensic examination, arriving at 1510 hours. At the time of the examination, Sandoval's friends had not yet been identified or interviewed.

Medical Forensic Examination

Diana Faugno, the SANE conducting the medical forensic examination in this case, collected a variety of swabs from in and on the victim's body, following standard protocol. Given the suspected drug-facilitated sexual assault, Faugno also collected blood and urine toxicological samples as soon as possible. She documented her findings in the [Medical Forensic Report for Case Study #3](#).



Using this report, please review the information to determine when and how the blood and urine samples for toxicology were collected.

What time was the blood sample for toxicology collected from the victim?

- 1600 1615 1640 1915

What time was the urine sample collected for toxicological analysis?

- 1600 1615 1640 1915

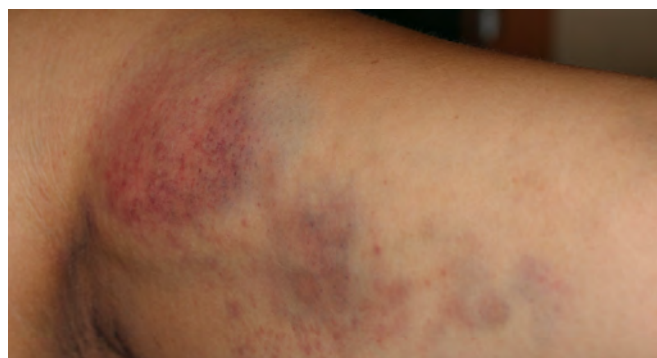Clothing Collected During the Exam

As part of the medical forensic examination, Faugno collected the bra and underwear Sandoval wore to the examination. The bra was the same one the victim wore the night before (at the time of the assault), but the underwear was a second pair she put on in the morning before calling the police and leaving for the examination. Faugno examined these items and documented her observations in the [Clothing Documentation Form for Forensic Examiners](#). She also photographed the clothing. Faugno noted that the condition of the victim's bra was unremarkable, but her underpants were blood stained.

Exam Physical Findings

Faugno summarized the visible physical findings from her examination of the victim:

- *Multiple lacerations at 6 o'clock on the posterior fourchette that goes down to the Perineum. Positive blue dye uptake.*
- *Abrasion from 4-7 o'clock on the fossa navicularis. Positive blue dye uptake. Pulls away when touched there.*
- *Multiple bruises on arms and legs.*
- *Laceration at 6 o'clock on the anal verge, positive blue dye uptake.*



Multiple bruises on the victim's arm from being grabbed and restrained.

While taking a patient history, the SANE also documented the subjective indicators of pain and injury described by the victim. Specifically, Faugno marked “YES” for the following items on the examination form, and then documented the victim’s responses:

Nongenital injury, pain, and/or bleeding: YES

“I feel really sore, my back hurts really bad, my shoulders and legs are sore.”

Anal-genital injury, pain and/or bleeding: YES

“It is just sore down there.”

For more information, please see the [Medical Forensic Report for Case Study #3](#).

Interpretation of Exam Findings

The SANE did not offer any conclusion or interpretation of the findings in this report, because the victim was unable to provide any history. However, the investigator will use the findings to inform the course of the investigation. For example, examination findings (combined with DNA testing) can often help to establish – or at least provide information about – any sexual acts that may have been committed and by whom.



In this case, do the exam findings corroborate any sexual acts that may have been committed? If so, which ones? (mark all that apply)

Oral copulation Vaginal penetration Anal penetration

Post-Examination Briefing

Following Sandoval’s examination, the SANE briefed the reporting officer. Faugno noted that the victim used the bathroom when she woke up, but she had not showered, bathed or douched. The victim also told the SANE she had not had consensual sex for several months, and Faugno relayed this information to Deputy Hafner.

Finally, Faugno informed Deputy Hafner that the photographs of the victim’s genital areas would be retained at the examination facility, but a digital card with photographs of the nongenital injuries were provided to Deputy Hafner. Photographs such as these can often be used to support an investigation and possible prosecution (including search warrants, arrest warrants, charging decisions, etc.).

Interviews and Evidence Collection

While the victim’s medical forensic examination was being conducted at the request of Deputy Hafner, a second Deputy, and the Deputy’s Sergeant, coordinated with the Campus Police Department to respond to the fraternity house, where they identified a number of fraternity members who were with the victim at the party at different times



throughout the evening. Several agreed to provide buccal swabs for DNA testing, but all denied having any sexual contact with the victim.

Investigator Assessment

At this point, the case was assigned to Detective Eisenga for follow-up. Using the information provided so far, please conduct an evaluation of the assault history, as an investigator would, before making a determination about next investigative steps.



Is the victim able to provide a narrative account of events?

- No Yes Unknown

Is there a starting point for the investigation regarding the number of suspects or the location of the suspected sexual assault?

- No Yes Unknown

How much time elapsed between the possible sexual assault and the victim's medical forensic examination?

- 1-4 hours 5-16 hours
 17-24 hours More than 24 hours

Where did the SANE document visible, physical injuries on the victim's body?
(mark all that apply)

- External vaginal structures
 External anal structures
 Other body parts (not genital)

Which items of the victim's clothing were collected in this case?
(mark all that apply)

- Underwear (worn to the party)
 Skirt (worn to the party)
 Blouse (worn to the party)
 Underwear (worn to the examination)
 Shirt (worn to the examination)
 Pants (worn to the examination)
 Bra (worn to the party and the examination)

Do reference samples need to be collected from any prior consensual sexual partner?

- No Yes Unknown



Toxicological Analysis

Because this case is a suspected drug- or alcohol-facilitated sexual assault (DFSA), the victim's blood and/or urine sample should be screened for drugs and possibly, blood alcohol content (BAC). According to the information provided by Sandoval, the medical forensic examination took place less than 24 hours following the suspected ingestion of drugs or alcohol. This has implications for the type of sample that is preferred for toxicological analysis. The SANE therefore filled out a [120-Hour Drug History Form](#).



In this scenario, which of the following is the sample of choice for toxicology testing? Why did you choose one sample over the other?

- Blood Urine

Prioritizing Items for Laboratory Analysis

In this scenario, there is no assault history to guide the evaluation of various evidentiary items – to make a determination regarding which may be most likely to yield probative biological material. Therefore, it is best to test all the items in the evidentiary kit, as well as some key articles of clothing. This would include the bra and underwear the victim wore to the examination (the bra was also worn the night before to the party).

However, if the investigator is limited to a certain number of evidentiary items in a laboratory service request, it will be critical to evaluate the evidence available and determine which items might be the most likely to yield probative biological material.



No Assault History

Even when the victim cannot provide a history of the assault, some information might be available from other sources to help guide this determination. For example, in this scenario there are visible physical findings documented by the SANE. As the investigation continues, additional information and evidence might emerge from suspect or witness statements, photographs, digital evidence, etc.

Again, we would like you to evaluate the evidentiary items collected in this case and determine their priority for laboratory analysis.



The items have been grouped in two categories: (1) Medical forensic examination of the victim and (2) Victim clothing. Please select 3-5 items from the following lists and rank them from highest (1) to lowest order of priority. Not all items will be included in the ranking.

Medical Forensic Examination of the Victim

_____ External peri-oral swabs taken from around the mouth (not the lips)

- Oral swabs from inside the mouth
- Fingernail scrapings/swabbings
- Body surface swabs (such as neck, breasts, thighs)
- External genital swabs
- Internal vaginal/cervical swabs
- External anal swabs
- Internal rectal swabs

Victim Clothing

- Underwear (worn at the time of the assault)
- Skirt (worn at the time of the assault)
- Blouse (worn at the time of the assault)
- Bra (worn at the time of the assault, and to the examination)
- Underwear (put on after the assault and worn to the examination)

Please describe the rationale for your rankings:

To see how the investigator evaluated the information and evidence available in this case, see the [Sexual Assault Case History and Analysis](#) report for Case Study #3.

Laboratory Findings

When the laboratory report was returned, the results indicated that semen was found on the victim's internal vaginal and internal anal swabs. DNA testing matched the profile found on these items to one member of the fraternity, Richard Allen. These results could therefore serve a variety of purposes in terms of this investigation.



Please mark the purposes that can be met with the information provided so far.

- Establish sexual contact
- Establish oral copulation
- Establish penile-vaginal penetration
- Establish penile-anal penetration
- Include suspect(s)
- Exclude suspect(s)
- Link local cases based on DNA developed from forensic evidence
- Corroborate the victim's statements
- Challenge the victim's statements
- Corroborate the suspect's statements
- Challenge the suspect's statements



The report also indicated that semen was found on a swab collected from the victim's mouth, and saliva was detected on the victim's right breast swab. DNA analysis matched both to a second member of the fraternity, John Kelly. Again, this evidence could serve various purposes in the investigation of this suspected sexual assault.



Please mark which of the following purposes are met with this evidence.

- Establish sexual contact
- Establish oral copulation (penetration of the victim's mouth with a penis)
- Include suspect(s)
- Exclude suspect(s)
- Link local cases based on DNA developed from forensic evidence
- Corroborate the victim's statements
- Challenge the victim's statements
- Corroborate the suspect's statements
- Challenge the suspect's statements

Evolving Defense: Denial to Consent

When confronted with these DNA results, both suspects switched from denial to a consent defense. To explain the victim's nongenital injuries, they both said the victim "liked it rough." In other words, both said they had sex with the victim, but the victim consented to the acts. In this case, the SANE's photo documentation and the diagrams of the victim's injuries are important evidence that will support additional investigative steps such as search warrants, arrest warrants, and charging by the prosecutor. Both suspects denied engaging in anal intercourse with the victim, but John Kelly admitted to consensual oral sex. They said they lied earlier because they were concerned about being sanctioned by the University.



Please describe the types of evidence and information that might be used to overcome a consent defense in this case.



Appendix F includes the following materials for Case Study #3: the [Medical Forensic Report for Case Study 3](#), the [Clothing Documentation by Forensic Examiners](#) completed by the SANE, the [Clothing Documentation by Law Enforcement](#) completed by Deputy Hafner, a [120-Hour Drug History](#) also completed by the SANE, and a completed [Sexual Assault History and Analysis](#).



Case Study #4: Forcible Rape and Sodomy by a Male Who Met a Female at a Party and Offered Her a Ride Home

Synopsis

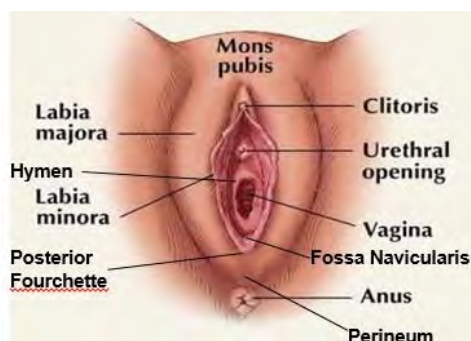
On August 8, 2015, the victim, 20-year old Madison Riggan, went to a party with friends, where she talked for quite a while with a man introduced as “Robert.” Robert is described as a white male, approximately 28 years old. Riggan had three beers while she was at the party. The victim said she drank the beers over several hours and she did not feel that she was intoxicated or incapacitated. She said that she does not engage in recreational drug abuse and she is not taking any prescription medications.

At approximately 0100 hours, Robert offered Riggan a ride home, but instead he took her to a deserted parking lot where he raped her vaginally and anally with his penis and at least one finger, in the front seat of his car. Riggan said Robert was on top of her so fast she didn’t know what to think. She tried to stop him, but he wouldn’t listen. Riggan is unclear if Robert wore a condom, but she believes he ejaculated inside her vagina.

After the rape, Robert drove Riggan home, where she immediately took a shower and changed into her pajamas, and then went to sleep. Later that day, she met with her boyfriend, and although she was upset, she did not tell him what happened. She was afraid he would get angry. They had consensual sexual intercourse at around noon, and her boyfriend did not wear a condom. Afterward, Riggan became even more upset and decided to report the rape to police.

Riggan called the police at approximately 1300 hours on August 9th, and Officer Wilson was dispatched to her home at 1330 hours. Wilson conducted a preliminary interview and worked to facilitate a medical forensic examination as soon as possible. Riggan told the officer that the clothing she was wearing at the time of the assault was on the floor in her bedroom. Officer Wilson collected the clothing, including a pair of pants, a bra, underwear, and a blouse. The officer also determined that Riggan put on pajamas after showering and those were also collected. He then transported the victim to Eisenhower Valley Women’s Institute for a medical forensic examination.

When Officer Wilson and the victim arrived at the hospital at 1600 hours, the officer briefed the SANE, Diana Faugno, with the information he had obtained so far, including the fact that he had collected the clothing the victim wore at the time of the sexual assault and those she put on after showering and before going to bed. When the examination was concluded, Faugno briefed the officer and turned over the evidence kit, including the underwear the victim wore to the examination. Since the victim was wearing her third change of clothing since the sexual assault, no other clothing was collected by the SANE at this time.



Medical Forensic Exam of the Victim

At this point, we would like you to review the [Medical Forensic Report for Case Study #4](#) and mark whether any of the following injuries were documented on the victim's forensic examination report.



Based on the SANE report, which of the following findings were documented during the genital examination?

- Abrasion from 5-7 o'clock of the posterior fourchette going up to the fossa navicularis with positive blue dye uptake
- Pulls away when touched in the area of the posterior fourchette
- Multiple lacerations on the posterior fourchette, extending down to the perineum
- Multiple bruises, redness, swelling to the hymen
- Superficial lacerations to the perineum and anal verge
- Complaint of pain from the perineum to the anus when touched
- Laceration at 12 o'clock on the anus

Remember, the posterior fourchette and the fossa navicularis are both vaginal structures, and they are the most common sites of genital injury in a sexual assault.

Evidence Collection

Next, please list the items of clothing collected in this case. Make sure to include clothing collected by the reporting officer as well as the SANE. Then answer some questions about the assessment and documentation of such clothing items.



Describe each item with the information needed to complete the property tag and impound the evidence in the property room.

When the officer and forensic examiner collect clothing items, do they need to visually examine them for any reason? Or should they simply collect and impound them?

- Clothing should simply be collected and impounded
- Clothing should be visually examined by the officer / forensic examiner

Describe some of the things an officer or forensic examiner might be looking for when examining the victim's (or suspect's) clothing?

What tool did we offer in this module specifically for the purpose of documenting these observations?

- SANE Exam Report Form
- Sexual Assault Case History and Analysis
- Laboratory Service Request
- Clothing Documentation Form

Interviews and Investigation

Detective Archambault was assigned to this investigation the following day, August 10th and that afternoon she interviewed the host of the party, as well as the victim's friends who were with the victim at the party. However, no one could identify "Robert," and they could not think of a person they knew who matched the description provided by the victim. When asked, no one remembered anyone taking pictures or recording video during the party and no surveillance cameras were identified in the area.

At the time, the victim's boyfriend was unwilling to provide a reference standard, so the laboratory would not be able to exclude him as the source of biological evidence in the event that a DNA profile was developed.

Investigator Assessment

With this information, we again offer a series of questions designed to guide your assessment of the evidence from the perspective of a law enforcement investigator.



As you evaluate the facts of this case, please mark all the following that apply:

- The victim is able to provide a narrative account of events.
- The victim's statement provides a starting point for the investigation regarding the specific acts committed and the identity of the suspect.
- The victim believes the suspect used a condom.
- The victim believes the suspect ejaculated.
- A reference standard is needed to exclude the boyfriend's DNA profile.

How much time elapsed between the sexual assault and the victim's examination?

- Less than 1 day (up to 24 hours)
- 1 -2 days (25-48 hours)
- 3-5 days (49-120 hours)
- More than 5 days (beyond 120 hours)

Is there any indication (so far) that toxicological analysis will be needed in this case?

- No
- Yes
- Unknown



Were reference samples collected from the consensual sexual partner?

No Yes Unknown

Case History and Analysis

Once again, we would like you to evaluate the evidentiary items collected in this case to determine their priority for laboratory analysis.



Please select 3-5 items from the following lists and rank them from highest (1) to lowest order of priority. Use the space below to describe the items and their ranking. Not all items will be included in the ranking.

Medical Forensic Examination

- _____ External peri-oral swabs taken from around the mouth (not the lips)
- _____ Oral swabs from inside the mouth
- _____ Fingernail scrapings/swabbings
- _____ Body surface swabs (such as neck, breasts, thighs)
- _____ External genital swabs
- _____ Internal vaginal/cervical swabs
- _____ External anal swabs
- _____ Internal rectal swabs

Victim Clothing

- _____ Blouse (worn at the time of the assault)
- _____ Pants (worn at the time of the assault)
- _____ Underwear (worn at the time of the assault)
- _____ Bra (worn at the time of the assault)
- _____ Pajamas (put on after showering)
- _____ Underwear (worn to the examination)

Please describe the rationale for your rankings:

Because policies, protocols, and forms will differ across agencies and laboratories, there is not going to be a single “right answer” on how to complete a Laboratory Service Request. However, we want to provide concrete guidance on what this might look like.

To see how the investigator evaluated the information and evidence available in this case, please see the [Sexual Assault Case History and Analysis](#) for Case Study #4. We also offer two examples of a Laboratory Service Request that might be submitted for this case scenario: One is in [Word format](#) and one is in [Excel format](#).



Laboratory Findings

Based on the history provided by the victim, the laboratory analyzed all the swabs in the evidence kit. The laboratory also analyzed the underwear the victim was wearing at the time of the sexual assault.

Results indicated that semen was identified on the victim's internal vaginal swab. DNA testing produced a DNA profile from an unknown male. No semen was found on the victim's underwear or on the anal swabs.



At this point do we know whose DNA is on the victim's vaginal swab?

Yes

No

In response to these laboratory results, the detective re-contacted the victim's boyfriend to explain that he needed to be excluded as the possible source of the semen found. The boyfriend agreed to provide a buccal swab, and his DNA profile matched the profile developed from the vaginal swab. Therefore, no suspect could be identified through DNA testing.

The detective continued the investigation until all viable leads were exhausted. The investigation was then inactivated, pending any new information or investigative leads.



Appendix E includes the [Medical Forensic Report for Case Study #4](#) and a completed [Sexual Assault Case History and Analysis](#) for this case, along with two versions of a Laboratory Service Request: One in [Word](#) and one in [Excel](#).

Case Study #5: Attempted Sexual Assault of a Female by a Male Stranger in a Park

Synopsis

On May 7, 2015, the 37-year old victim, Estela Camacho, was walking through Riverview Park on a popular hiking trail. At about 0600 hours, she was assaulted from behind by a stranger who placed both his hands under her clothing near her abdominal area. Camacho was unable to get a good look at the suspect's face, but she believes he may be homeless because he smelled as though he hadn't bathed for some time. The suspect reached up and placed his hands over Camacho's mouth in an attempt to keep her from yelling for help.

The victim and suspect briefly struggled and Camacho was able to free herself long enough to scream, which drew the attention of two individuals who witnessed the attack. The suspect then fled on foot, and the two witnesses came to the aid of the victim, and immediately called 911.



The witnesses described the suspect as a white male in his 40's. A number of officers responded to the area to start searching the park for possible suspects. Officer Jones contacted the victim at 0610 hours. After obtaining the victim and witness statements, Officer Jones called the Major Crimes Unit to talk to a detective. Detective Bradley asked Officer Jones to transport the victim to Eisenhower Valley Women's Institute for an abbreviated forensic examination, specifically making sure to have the medical forensic examiner swab the outside area of the victim's mouth.



Photo Credit: Shutterstock.com

Medical Forensic Exam of the Victim



Below you will find a list of the biological evidence that could potentially be collected in a medical forensic examination. Please mark which of the following items you believe should be collected in this case study.

- External peri-oral swabs taken from around the mouth (not the lips)
- Oral swabs from inside the mouth
- Fingernail scrapings/swabbings
- Swabbings of the fingers
- Body surface swabs (such as neck, breasts, thighs)
- External genital swabs
- Internal vaginal/cervical swabs
- External anal swabs
- Internal rectal swabs

To see what steps were taken in this case study, and the findings documented by the forensic examiner, please review the [Medical Forensic Report for Case Study #5](#).

Interviews and Investigation

Detective Bradley was called out to the scene. Both witnesses were able to provide a good physical description of the suspect. A composite sketch was created and distributed throughout the park and the surrounding neighborhood.

The first responding officer and the detective both believed the suspect intended to sexually assault the victim, but he fled when she screamed.

Investigative Steps

Because the struggle between the victim and suspect was brief, it is likely that minimal amounts of DNA were exchanged between the two. This will have implications for the specific laboratory analysis conducted.

In this case, Detective Bradley requested laboratory analysis of the swabs taken from the victim's abdomen, fingers, and mouth area, and the laboratory used Y-screening methods to test for the presence of male DNA. This has implications for the next investigative steps, including whether the detective will collect any DNA reference standards from other males.



At this point, should the investigator obtain a DNA reference standard from the victim's husband or any other male who might have had consensual contact with the victim's abdomen, fingers or mouth?

Yes No

Why is it important to obtain a reference standard from any males who came into recent contact with the victim's abdomen, fingers or mouth?

Laboratory Findings

When the laboratory results were reported, the swab from the victim's abdomen indicated the presence of female DNA only. However, the swabs from outside the victim's mouth detected the presence of male DNA, even though the vast majority of the DNA originated from a female (in this case, the victim). Using Y-STR technology, the laboratory was able to produce a DNA profile.



At this point do we know that the Y-profile belongs to the suspect?

Yes No

Next Investigative Steps

Four days later, a transient in the park was recognized from the composite sketch. Detective Bradley was able to use the information obtained from the concerned citizen to identify and locate the suspect. When contacted, the suspect voluntarily agreed to provide a DNA reference standard. If he had been located promptly after the assault, it would have been important to swab the suspect's fingers for any biological material originating from the victim (e.g., saliva, epithelial cells). However, this was not done in this case, given the length of time that elapsed since the sexual assault.

During the course of the investigation, several other possible suspects provided reference standards as well. However, Y-testing revealed that the Y-profile from the victim's mouth matched the transient suspect and he ultimately confessed to the attack.





Based on the information provided in this case study, do you believe this case would be charged as an attempted rape or a battery in your jurisdiction? Please explain.



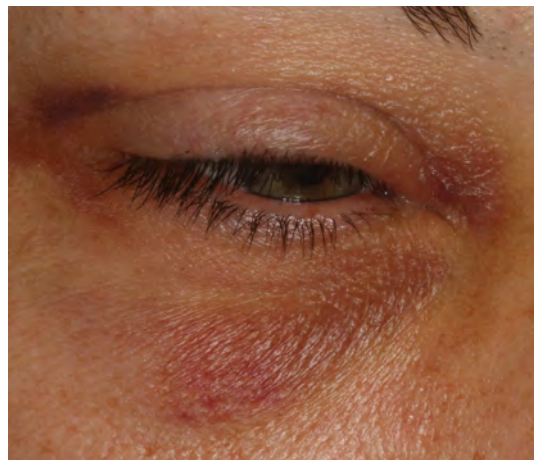
Appendix F includes the [Medical Forensic Report for Case Study #5](#).

Case Study #6: Forcible Oral Copulation of 22-Year-Old Male by a Male Acquaintance

Synopsis

On April 19, 2018, at approximately 2300 hours, the 22-year-old victim, George Wells, was at the house of a friend of a co-worker he identified as Clifton Sparks, when Sparks forcefully orally copulated the victim's penis. Sparks is approximately 20 years old. On April 20, 2018, at approximately 1030 hours, Wells was transported by Officer Louis Colon to Eisenhower Medical Center for a medical forensic examination that was conducted by Sexual Assault Nurse Examiner, Diana Faugno.

Wells said he went to Clifton's house to hang out and they were "smoking weed and drinking shots." Wells said they were watching a movie, and he was on the couch while Sparks was on the bed. Sparks started pressuring the victim to let him give Wells a massage, promising that he would not "try anything." He said Sparks wanted to rub Wells' legs and arms and he tried to bribe him with \$1,000 if he would give him a "blow job." Wells said no, and Sparks seemed to let it go but then he wanted Wells to show him his penis. Wells said he "caved" and agreed to show him, but that Sparks had to stay all the way over on the other side of the room.



Sparks complied, and then Wells started to get dressed but Sparks said he wanted to keep giving Wells a back massage. Wells said he went to put on his shorts, but Sparks grabbed his shorts, so he could not get them on. Wells put his arm up and pushed Sparks back, but Sparks went into the bathroom and brought back a gun. Sparks waved the gun at Wells and then hit Wells in the face with his closed fist.

Sparks told Wells to get up and get on with it. Wells said he was scared because he thought Sparks was going to kill him, so he did what he wanted. Wells said at this point he was on the couch and the suspect began orally copulating the victim's penis until he



ejaculated in the suspect's mouth. Wells said Sparks took a picture of Well's "dick" in Sparks' mouth and he made sure Wells' face was in the picture. Sparks then went to take Wells' pants off, but Wells again told him to "stop and no." Wells denied any anal penetration and he said he was not forced to orally copulate the suspect.

Sparks said that if Wells told anyone what happened, he would come after him. Wells said Sparks knew that Wells is moving out of state, but Sparks said he knows that Wells' son is not moving with him and he will continue to still live in the area. Wells said that he took this as a threat against his son and he did what Sparks wanted and then he called an Uber. When the Uber arrived, Wells said he ran out and jumped in the car.

Wells said he got home at about 0100 hours and he tried to sleep but he couldn't. When he got up in the morning, he told his roommate and then he called the police at about 1000 hours because he was scared. Officer Colon responded to Wells' home to take a preliminary report of the sexual assault. After talking to Wells, Officer Colon identified and collected the clothing Wells was wearing at the time of the assault, and he later impounded the clothing in the evidence property room per Department policy.

Exam Physical Findings

Nurse Faugno summarized the visible physical findings from her examination of the victim:

- *No visible injuries to the external genitalia or perineal area.*
- *1-centimeter laceration to the right eyebrow with blood present.*



Is the absence of visible injuries to the victim's genitalia consistent or inconsistent with the history provided? Please explain.



To review the physical findings from the examination of this male victim, please see the [Medical Forensic Report for Case Study #6](#) in Appendix E.

Investigator Assessment

Based on the information so far, and the report from the medical forensic examination, please evaluate the evidence from the perspective of a law enforcement investigator.



Did the victim have any sexual contact with anyone during the previous 5 days?

Yes No

Did the victim shower or bathe between the time of the assault and the medical forensic examination?

Yes No

Did the Sexual Assault Nurse Examiner (SANE) collect the victim's clothing?

Yes No

If the victim's clothing was not collected at the time of the medical forensic examination, why not?

Interviews and Investigation

The Sex Crimes detective assigned to this case ran a criminal history check on Sparks and Wells, and both were negative. The detective then contacted the victim at his home two days after the preliminary report was taken.

At that point, the victim said he only called the police because he was afraid for his life as well as the safety of his young son. Wells said he only wanted police to know what happened in case the suspect had ever been involved in another sexual assault or in case he came after him or his son. Wells was adamant that he does not want to pursue the investigation or prosecution since he is leaving the state for a new job opportunity.

The investigator recommended identifying a rape crisis center once Wells relocated, so he could access any supportive services he might need in the future. He also advised Wells that the evidence collected from the sexual assault examination would be retained as evidence, as well as the clothing the patrol officer impounded during the preliminary investigation. Wells was advised that the investigation could be reopened within the 10-year statute of limitation if he changed his mind, but also that the investigation and any potential prosecution may be more difficult because of the delay in conducting a thorough investigation. Wells said he understood, but he was sure that he just wanted to put this incident behind him for the time being.

Prioritizing Items for Laboratory Analysis

In this case, the victim did not want law enforcement to conduct any further investigation of his sexual assault report. Typically, this means that no evidence should be submitted to the laboratory for analysis. However, for the purpose of this exercise, let's imagine that the victim *did* choose to participate in the investigation. Based on the facts of this case, which items collected during the victim's medical forensic exam would an investigator most likely submit for analysis, in order to advance the investigation?



Please identify which items of evidence you would be most likely to ask the laboratory to analyze, if the victim was participating in the investigation.

Medical Forensic Examination

- External peri-oral swabs taken from around the mouth (not the lips)
- Oral swabs from inside the mouth
- Fingernail scrapings/swabbings
- Swabbings of the fingers
- Body surface swabs (such as neck, back, thighs)
- External penile swabs
- External scrotal swabs
- External anal swabs
- Internal rectal swabs

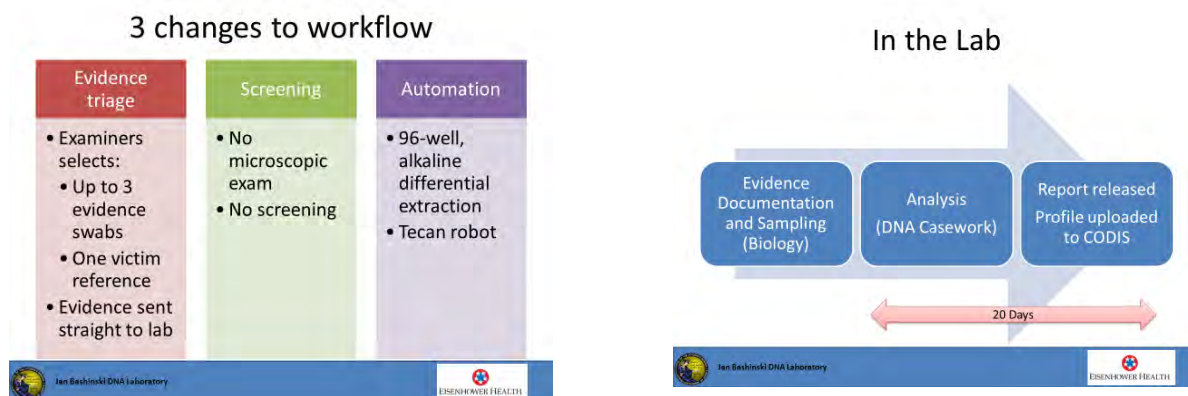
Please describe the rationale for your rankings:

Laboratory Findings

This case study took place in California, where the forensic examiner program was participating in a Rapid DNA Service (RADS) for sexual assault kits. This means the California Department of Justice's DNA laboratory was working with four California counties to test a portion of all sexual assault kits within 20 days.

This process begins with the forensic examiner selecting up to three swabs and sending them – along with a reference standard from the victim – straight to the DNA laboratory. The investigator provides a case number but waits to submit any other evidence for additional testing depending on the Rapid DNA test results. In the RADS program, the laboratory does not use a microscope to visualize the evidence or screen any samples prior to conducting DNA analysis. The swabs that are submitted by the forensic examiner proceed directly to the stage of developing a DNA profile. Within 20 days, laboratory personnel complete the analysis, release the report to law enforcement, and upload the profile to CODIS. In addition, the forensic examiner program is informed if a searchable profile was obtained from any of the swabs submitted; if so, they are also notified which swab produced the searchable profile, which allows the forensic examiner program to track the results based on the specific type of swabs.





Returning to the case study, the forensic examiner program received a report from the DNA laboratory as a result of the RAD program, indicating that a CODIS searchable profile was obtained from the victim's scrotal swabs.

Inactivating the Investigation

Despite this laboratory result, the investigator inactivated the crime report pending a change in the victim's wishes regarding participation or the discovery of new evidence. The investigator also notified the DNA laboratory that the investigation had been suspended, and following the investigator's Department policy, the foreign DNA profile recovered from the victim's scrotal swab was removed from CODIS.



Based on the information presented, would law enforcement agencies in your jurisdiction proceed with the investigation despite the victim's stated wish to suspend the investigation?

Would agencies in your jurisdiction notify the laboratory to remove the foreign DNA profile obtained from the medical forensic examination when a victim chooses not to participate in an investigation and potential prosecution?

What are the pros and cons of both options (removing or not removing the DNA profile from CODIS)?

Conclusion

To conclude this module, we want to return to the questions posed in the introduction: Why is attrition so high for sexual assault cases in the criminal justice system? And what makes these cases so difficult to successfully investigate and prosecute?

As we noted, one factor is the difficulty in proving the legal elements beyond a reasonable doubt. This module is designed to address this challenge by exploring the evidentiary items and samples that can be obtained from forensic examinations conducted with sexual assault victims and suspects. The reality is that physical evidence can often be collected and documented in these cases, if investigators know where it might be found and how it can meaningfully advance the investigation.

We hope this material will increase professionals' understanding of what role forensic examinations of the victim and suspect play in a sexual assault investigation. Our goal is to encourage professionals involved in these cases to push past traditional ways of thinking about the evidence from a forensic examination, to critically analyze how each piece of information gathered fits into the complicated puzzle of an entire investigation. Only then will we be able to tackle the challenge of attrition and better serve the interests of sexual assault victims, their loved ones, and our entire communities.



Appendix A. Purposes of Common Evidentiary Samples³⁶

Common Samples from Forensic Examinations of Sexual Assault Victims and Suspects	Possible Evidence	Potential Investigative Purposes
<p>Clothing</p> <ul style="list-style-type: none"> -If victim is wearing the same clothes worn during, or immediately after the assault (if not, identify the location of that clothing and secure) -If victim has changed clothes since the assault, consider evidentiary relevance of collecting underwear worn to the examination -For suspects, coordinate with law enforcement regarding what specific clothing items to collect 	<ul style="list-style-type: none"> -Biological or other foreign material (transferred from or touched by the suspect or victim, or transferred from the crime scene) -Alterations to clothing as a result of the assault 	<ul style="list-style-type: none"> -Evidence on, or alterations to clothing may corroborate case facts or document force (e.g., torn, stretched, missing button) -Biological material found on clothing may identify or exclude a suspect, or link a suspect to the victim or crime scene
<p>Used condoms, tampons, or sanitary pads</p> <ul style="list-style-type: none"> -If a tampon or sanitary pad was worn at the time of the assault or immediately following -If a used condom or condom wrapper is found in or on the body, or brought to the exam <p>Other items connected to assault (e.g., object used to penetrate, tissues or towels used after the assault)</p>	<ul style="list-style-type: none"> -Biological or other foreign material 	<ul style="list-style-type: none"> -Evidence on these items, or the items themselves may corroborate case facts -Biological material may also identify or exclude a suspect, or link a suspect to the victim or crime scene
<p>Body surface swabs and specimens</p> <ul style="list-style-type: none"> -If there are areas on victim's skin where saliva, semen, or other biological material from the suspect may have been deposited or left by touching - If there are areas on the suspect's skin where biological material from the victim may have been deposited or left by touching -If foreign material or debris are detected (e.g., blood, dried secretions, fibers, loose hairs, vegetation, soil, fingernail swabs, scrapings or clippings, matted hair cuttings, material dislodged from mouth, bite marks, and swabs of suspected semen and saliva) -If other items were worn or used by the victim or suspect during or immediately after the assault (e.g., eye glasses, prosthetics, wheelchairs, scooters, canes, wheelchair pads, and assistive communication devices). Evidence might even be on service animals. 	<ul style="list-style-type: none"> -Biological or other foreign material 	<ul style="list-style-type: none"> -Biological material found on the victim's body surface may identify or exclude a suspect or establish sexual contact -If found on a suspect, biological material may link a suspect to the victim or crime scene -Foreign material may also corroborate case facts or document force (e.g., torn fingernails, bite marks, broken tooth)
<p>Hair</p> <ul style="list-style-type: none"> -Hair may be found on body surface or clothing -Hair combings, if it is disclosed or suspected that the suspect's hair may have been transferred to crime scene or to the victim's body OR if the victim's hair may have been transferred to the suspect or crime scene -If so, hair reference samples are required 	<ul style="list-style-type: none"> -Foreign material (the hair or other items in the hair) -Hair reference sample for victim -Hair reference sample for suspect 	<ul style="list-style-type: none"> -Hair reference samples are used to distinguish victim hair characteristics from foreign hair characteristics -Foreign hair may serve to associate a suspect with the victim, corroborate case facts, or document force (e.g., victim

³⁶ This chart was created by Kristin Littel, with the concept and some text adapted in part from a variety of sources, including Day and Pierce-Weeks (2013), Office on Violence Against Women (2016), and (Technical Working Group on Biological Evidence Preservation, 2013).



Common Samples from Forensic Examinations of Sexual Assault Victims and Suspects	Possible Evidence	Potential Investigative Purposes
		or suspect may have pulled hair during the assault)
<p>Oral swabs -When there may have been genital or oral penetration -When there may have kissing or transfer of saliva in the victim's or suspect's mouth -When case facts are unknown or there is little history</p>	Biological or other foreign material	<p>-Biological material may identify or exclude a suspect, link a suspect to the victim, or establish sexual contact -Biological or other foreign material found may also document force or corroborate case facts (e.g., blood in mouth)</p>
<p>External genitalia and cervical-vaginal swabs -If possible vaginal-penile penetration, other genital-to-genital contact, or contact that could have left biological material including oral-to-genital Penile swabs -If possible penile-vaginal penetration, other genital-to-genital contact, oral contact, anal or rectal contact, or foreign material disclosed or suspected (e.g., lubricant) Anorectal swabs (perianal and anal canal) -If possible anal-penile or rectal-penile penetration, oral-anal penetration or contact, digital or foreign object penetration -If there was vaginal or anal penetration, biological material (e.g., semen) may have leaked into the perineal area Genital swabs (as a general category) -If there is little or no assault history available (e.g., as may occur in a drug-facilitated sexual assault), it may be appropriate to collect any or all of the above swabs, depending on what is known about the case</p>	Biological or other foreign material	<p>-Biological material may identify or exclude a suspect, associate a suspect with the victim or crime scene, or establish sexual contact -Biological or other foreign material found may also document force or corroborate case facts (e.g., blood)</p>
<p>Buccal (cheek) swabs -For DNA reference standards from the victim or suspect, unless it is medically or forensically necessary to take a blood sample instead</p>	<p>- DNA reference standard for victim -DNA reference standard for suspect</p>	<p>- To distinguish victim DNA profile from foreign DNA - To distinguish suspect DNA profile from foreign DNA</p>
<p>Blood -If found on body, clothing, or other items -If buccal swab or saliva sample is not acceptable for DNA reference standard (either victim or suspect) -For toxicology testing, if collected within 24 hours of the assault</p>	<p>-DNA profile -Evidence of injury or transfer from menstruating female -Presence of alcohol or drugs in blood</p>	<p>-If DNA reference standard, used to distinguish victim DNA profile from foreign DNA and suspect DNA profile from foreign DNA -Blood may identify or exclude a suspect, associate a suspect with the victim or crime scene, corroborate case facts, or document force -Presence of alcohol or drugs in blood may corroborate case</p>



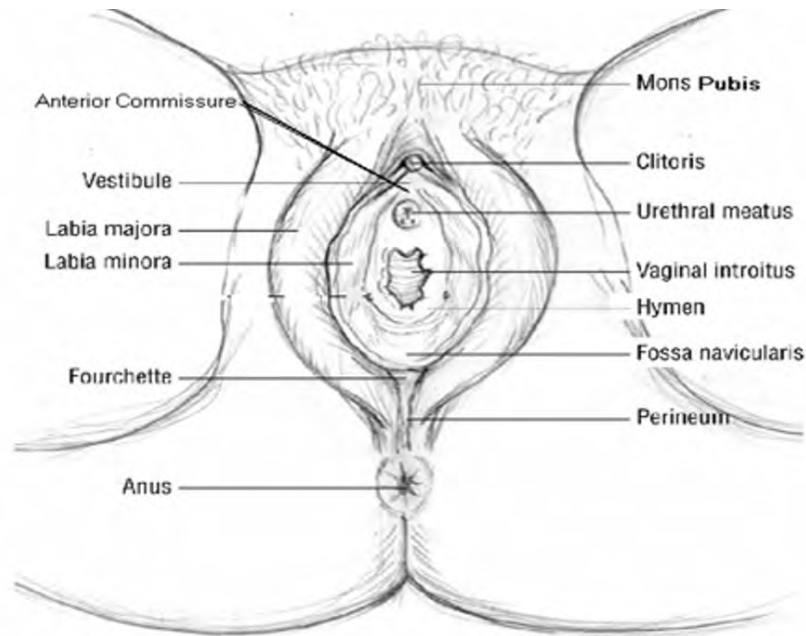
Common Samples from Forensic Examinations of Sexual Assault Victims and Suspects	Possible Evidence	Potential Investigative Purposes
		facts, including level of victim incapacitation
Urine -For toxicology testing, if collected within 120 hours of the assault	-Presence of alcohol or drugs in urine	-Alcohol or drugs in urine may corroborate case facts, including level of victim incapacitation -Foreign DNA profile found may identify or exclude suspect ³⁷

³⁷ Urine contains cellular material from an individual that may be used to develop a full or partial DNA profile. However, urine has less cellular material than blood, semen, or saliva, because it is not inherent in the fluid. The source of a DNA profile is not the urine itself, but cells shed from the body during the process of urination.

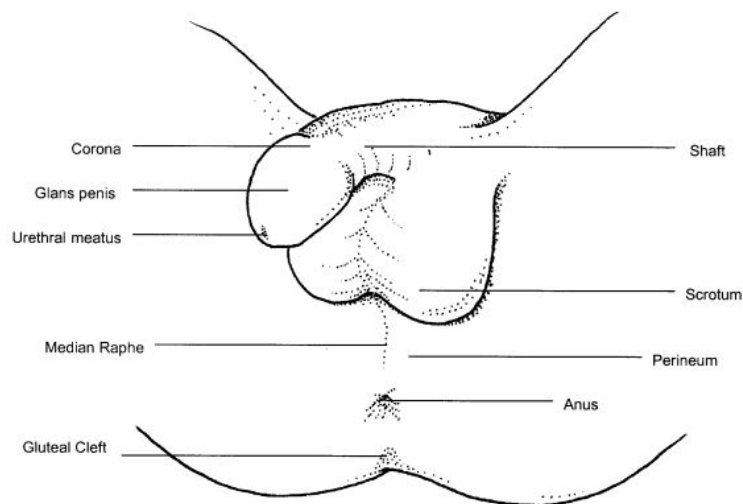


Appendix B. Female and Male Genital Anatomy Illustrations³⁸

Female Genital Anatomy



Male Genital Anatomy



³⁸ The adult/adolescent female genital illustration was provided by Diana Faugno and the male genital anatomy illustration is from the California Office of Emergency Services, OCJP form 923M.

Appendix C: Examples of Nongenital Physical Findings³⁹

Head and scalp. Injury findings might include areas of missing hair and tenderness, bruising, or petechiae on the scalp. (Petechiae are pinpoint flat round red spots under the skin surface caused by intradermal hemorrhage, or bleeding into the skin.)

Eyes. Injury findings might include tenderness/bruising around the eyes and presence of conjunctival petechiae or hemorrhage.

External and internal ears. Injury findings might include tenderness/bruising, bleeding, or leakage of cerebrospinal fluid (CSF) from the ear.

Nose and mouth: Injury findings might include bleeding or leakage of cerebrospinal fluid (CSF) from nose, or areas of bruising on the outside of the nose; injury and buccal mucosa on the lips, gums, and tongue, petechiae on the hard/soft palate, and the frenulum.

Neck: Injury findings might include subcutaneous emphysema and ligature marks, abrasions, petechia or red bruising from bites or sucking.

Hands: Range of external injuries might be found. Wrists may have signs of ligature, or marks/bruising consistent with restraint.

Forearms: Range of tenderness or injuries might be found. Circulation and sensation issues, and limited range of motion may be noted, as well as intravenous puncture sites.

Upper and under arms: Range of tenderness/injuries might be found, including “fingertip” bruising if restrained by hands. Circulation, sensation, and limited range of motion may be noted.

Breasts and trunk: Subtle or obvious injury or tenderness may be seen in a variety of places on the trunk and breasts. Breast injury may include sucking and bite marks.

Back: Subtle or obvious injury or tenderness may be seen.

Abdominal region: Subtle or obvious injury or tenderness may be seen. There may also be internal trauma.

Anterior and posterior aspects of the legs: Subtle or obvious injury/tenderness may be seen, especially to inner thighs. Also note limited range of motion, including feet and ankles.

General: Appearance, hygiene, clothing condition, vital signs, weight/height, demeanor, orientation. Physical deformities. For victims, piercings and other body markings are noted only if they relate to the crime (for example, if the victim was tattooed before the assault, as sometimes seen in trafficking cases). For suspects, such markings are always documented along with other characteristics. Any of this information might potentially identify a suspect or corroborate the account of events as described by the victim, suspect, or any witnesses.

³⁹ Chart was adapted from Office on Violence Against Women (2016).

Appendix D: Anatomy Evaluated During Genital Examination⁴⁰

Female	Male
<ul style="list-style-type: none"> • Vulva: external female genitals • Labia majora: outer folds of skin that protect the more delicate structures underneath • Labia minora: inner folds of tissue that cover the vaginal and urinary openings • Fossa navicularis: shallow depression at the bottom of the vulva, in front of the posterior fourchette • Posterior fourchette: fold of mucous membrane that connects the labia minora at the base of the vulva • Urethra: urinary opening • Posterior fornix: back of the vagina behind the cervix • Introitus: vaginal opening • Hymen: collar or semi-collar of tissue around the opening of the vagina • Vagina: muscular tube that serves as a passageway between the uterus and the outside of the body • Uterus: hollow muscular organ (pear-shaped); it is where the fetus grows before birth • Cervix: lower portion of the uterus that protrudes into the vagina • Os: entrance to the cervix • Rectum: terminal portion of the lower intestine • Anus: muscular ring that serves as the opening of the rectum • Perineum: bridge of flesh between the vulva and the anus 	<ul style="list-style-type: none"> • Penis: male organ of reproduction and urination • Shaft: cylindrical portion of the penis • Glans: cone shaped head of the penis • Foreskin (prepuce): moveable hood of skin that covers the glans of the penis; this structure is sometimes removed during circumcision • Urethra: urinary opening in the end of the penis • Scrotum: double pouch of skin that holds the testicles • Testicles: egg shaped reproductive glands that produce spermatozoa; housed in the scrotum • Semen: thick fluid released by the male during ejaculation; mixture of fluids from various glands plus the spermatozoa • Ejaculation: release of reproductive fluid via the male urethra; the ejaculate may or may not contain spermatozoa • Perineum: bridge of skin between the scrotum and anus • Rectum: terminal portion of the lower intestine • Anus: muscular ring that serves as the opening of the rectum

⁴⁰ Chart adapted from National Judicial Education Program (2002).



Appendix E. Sample Investigator Follow-Up Reports

- [Drug-Facilitated Sexual Assault](#)
- [Stranger Sexual Assault](#)
- [Template for an Investigator's Follow-Up Report](#)



Appendix F. Case Study Materials

Case Study #1

- [Medical Forensic Report for Case Study #1](#)
- [Sexual Assault Case History and Analysis](#)

Case Study #2

- [Medical Forensic Report for Case Study #2](#)
- [Clothing Documentation by Forensic Examiner](#)
- Suspect Forensic Examination reports for [Max Verduzco](#) and [Tyrone Crosby](#)
- [Sexual Assault Case History and Analysis](#)

Case Study #3

- [Medical Forensic Report for Case Study #3](#)
- [Clothing Documentation by Forensic Examiner](#)
- [Clothing Documentation by Law Enforcement](#)
- [120-Hour Drug History by Forensic Examiner](#)
- [Sexual Assault Case History and Analysis](#)

Case Study #4

- [Medical Forensic Report for Case Study #4](#)
- [Sexual Assault Case History and Analysis](#)
- [Laboratory Service Request: Word Format](#)
- [Laboratory Service Request: Excel Format](#)

Case Study #5

- [Medical Forensic Report for Case Study #5](#)

Case Study #6

- [Medical Forensic Report for Case Study #6](#)

Appendix G: Blank Case Study Forms and Other Tools

Case Study Forms

This Appendix includes blank forms, many of which were used in the case studies, that may be adapted for use by law enforcement agencies and forensic examiner programs:

- San Diego County [Clothing Documentation Form for Forensic Examiners](#)
- San Diego County [Clothing Documentation Form for Law Enforcement](#)
- San Diego Police Department [120-Hour Drug History Form for Forensic Examiners \(DFSA\)](#)
- San Diego Police Department [Sexual Assault Case History and Analysis](#)
- Two Sample Laboratory Service Request Forms to be Completed by Investigators. One version in [Excel](#) and one in a [Word Document](#)
- San Diego Police Department [Instructions for Obtaining Buccal \(mouth\) Swabs](#)
- [Consent Form for Conducting a Suspect Examination from COVERSA](#)
- [Consent Form for Obtaining a DNA Reference Standard](#)
- San Diego County [Template Affidavit and Search Warrant Suspect Exam](#)
- San Diego County [Sample CODIS Confirmation Affidavit Search Warrant](#)
- King County [Template Affidavit to obtain a Search Warrant for a Suspect Exam](#)

Other Tools

Sample Examination Report Forms – Adult/Adolescent Victims (fillable)

- State of California, Office of Emergency Services, [OCJP 923 Form](#), [Instructions](#) and [Protocol](#)
- Adaptable version of a victim examination OCJP 923 [Form](#) created by [SDFI](#) and Eisenhower Medical Center, Rancho Mirage, California

Sample Examination Report Forms – Suspects

- State of California, Office of Emergency Services [OCJP Form 950](#), [Instructions](#) and [Protocol](#)
- [North Dakota](#) Suspect Forensic Exam Form



References

American College of Emergency Physicians (Ed.) (2013). [*Evaluation and management of the sexually assaulted or sexually abused patient \(2nd ed.\)*](#).

Archambault, J. (2000). [*Do you snip or pluck a victim's head and pubic hair?*](#) *Sexual Assault Report*, 3 (5), 65, 79-80.

Baker, R.B. & Sommers, M.S. (2008). Relationship of genital injuries and age in adolescent and young adult rape survivors. *Journal of Obstetric, Gynecologic, and Neonatal Nursing*, 37 (3), 282-289.

Brayley-Morris, H., Sorrell, A., Revoir, A.P., Meakin, G.E., Court, D.S. & Morgan, R.M. (2015). Persistence of DNA from laundered semen stains: Implications for child sex trafficking cases. *Forensic Science International: Genetics*, 19, 165-171.

Breathnach, M., Williams, L., McKenna, L. & Moore, E. (2015). Probability of detection of DNA deposited by habitual wearer and/or the second individual who touched the garment. *Forensic Science International: Genetics*, 20, 53-60.

Briggs, M., Stermac, L.E. & Divinsky, M. (1998). Genital injuries following sexual assault of women with and without prior sexual intercourse experience. *Canadian Medical Association Journal*, 159 (1), 33-37.

Byard, R.W. & Langlois, N.E.I. (2015). Bruises: Is it a case of 'the more we know, the less we understand?' *Forensic Science, Medicine, and Pathology*, 11 (4), 479-481.

Cain, I.T. (2002). *The use of physical evidence in the investigation and prosecution of sexual assault cases* (Unpublished master's thesis). National University, La Jolla, CA.

Campbell, R. (2008). The psychological impact of rape victims' experiences with the legal, medical and mental health systems. *American Psychologist*, 63 (8), 702-717.

Campbell, R., Bybee, D., Townsend, S.M., Shawn, J., Karim, N. & Markowitz, J. (2014). The impact of Sexual Assault Nurse Examiner (SANE) programs on criminal justice case outcomes: A multisite replication study. *Violence Against Women*, 20 (5), 607-625.

Campbell, R., Patterson, D. & Bybee, D. (2012). Prosecution of adult sexual assault cases: A longitudinal analysis of the impact of a sexual assault nurse examiner program. *Violence Against Women*, 18 (2), 223-244.

Campbell, R., Pierce, S.J., Sharma, D.B., Feeney, H., Goodman-Williams, R. & Ma, W. (2018). *Serial sexual assaults: A longitudinal examination of offending patterns using DNA evidence*. Final report for National Institute of Justice, grant number 2014-NE-BX-0006.

Carter-Snell, C.J. (2007). Understanding women's risk for injury from sexual assault (Unpublished doctoral dissertation). University of Alberta, Edmonton, Alberta, Canada.



Casali, M.B., Palazzo, E., Blandino, A., Battistini, A., Motta, F. Kustermann, A. & Cattaneo, C. (2017). The adult male rape victim: Forensic description of a series of 57 cases. *American Journal of Forensic Medical Pathology*, 38 (3), 175-179.

Centers for Disease Control and Prevention [CDC] (2016). [2016 sexually transmitted diseases surveillance](#). Atlanta: US Department of Health and Human Services.

Choudhary, E., Gunzler, D., Tu, X. & Bossarte, R.M. (2012). Epidemiological characteristics of male sexual assault in a criminological database. *Journal of Interpersonal Violence*, 27 (3), 523-546.

Crandall, C. & Helitzer, D. (2013). *Impact evaluation of a Sexual Assault Nurse Examiner (SANE) program*. Final report for National Institute of Justice, grant number 98-WT-VX-0027. NCJ 203276, available at <http://www.ncjrs.gov>

Davies, A. (1978). A preliminary investigation using p-nitrophenyl phosphate to quantitate acid phosphatase on swabs examined in cases of sexual assault. *Medicine, Science, and the Law*, 18 (3), 174-178.

Day, K. & Pierce-Weeks, J. (2013). [The clinical management of children and adolescents who have experienced sexual violence: Technical considerations for PEPFAR programs](#). Arlington, VA: USAID's AIDS Support & Technical Assistance Resources, AIDSTAR-One, Task Order 1 (ANNEX 9, CLINICIAN'S ROLE IN EVIDENCE COLLECTION JOB AID).

Drocton, P., Sachs, C., Chu, L. & Wheeler, M. (2008). Validation set correlates of anogenital injury after sexual assault. *Academic Emergency Medicine*, 1 (3), 231-238.

Faugno, D.K., Trujillo, A.C., Bachmeier, B.A. & Speck, P.M. (2017). *Manual nonfatal strangulation assessment for healthcare providers and first responders*. Florissant, MO: STM Learning.

Faugno, D., Waszak, D., Strack, G.B., Brooks, M.A. & Gwinn, C.G. (2013). Strangulation forensic examination: Best practice for health care providers. *Advanced Emergency Nursing Journal*, 35 (4), 314-327.

Gingras, F., Paquet, C., Bazinet, M., Granger, D., Marcoux-Legault, K., Fiorillo, M., Séguin, D., Balzer, F., Chamberland, C. & Jolicoeur, C. (2009). Biological and DNA evidence in 1000 sexual assault cases. *Forensic Science International: Genetics Supplement Series*, 2 (1), 138-140.

Golden, G.S. et al. (2015). Bite-mark and pattern injury analysis: A brief status overview. *Journal of the California Dental Association*, 43 (6), 309-314.

Graf, C. (2009). [Genital injury and human sexual response in sexual assault](#) [PowerPoint slides].

Green, W. (1988). *Rape: The evidential examination and management of the adult female victim*. Lanham, MD: Lexington Books.

Grossin, C., Sibille, I. Lorin de la Grandmaison, G., Banasr, A., Brion, F. & Durigon, M. (2003). Analysis of 418 cases of sexual assault. *Forensic Science International*, 131 (2-3), 125-130.

Hess, S. & Haas, C. (2017). Recovery of trace DNA on clothing: A comparison of mini-tape lifting and three other forensic evidence collection techniques. *Journal of Forensic Science*, 62 (1), 187-191.

Hillman, R.J., O'Mara, N., Tomlinson, D., & Harris, J.R.W. (1991). Adult male victims of sexual assault: An underdiagnosed condition. *International Journal of STD & AIDS*, 2 (1), 22-24.

Hillman, R.J., Tomlinson, D., McMillan, A., French, P.D. & Harris, J.R.W. (1990). Sexual assault of men: A series. *Genitourinary Medicine*, 66, 247.

International Association of Forensic Nurses [IAFN] (2016). [*The evaluation and treatment of non-fatal strangulation in the health care setting*](#). Arnold, MD: Author.

Jones, J., Dunnuck, C., Rossman, L., Wynn, B. & Genco, M. (2003). Adolescent Foley catheter technique for visualizing hymenal injuries in adolescent sexual assault. *Academic Emergency Medicine*, 10 (9), 1001-1004.

Jones, J. S., Rossman, L., Wynn, B. N., Dunnuck, C. & Schwartz, N. (2003). Comparative analysis of adult versus adolescent sexual assault: Epidemiology and patterns of anogenital injury. *Academic Emergency Medicine*, 10 (8), 872-877.

Kaufman, A., Divasto, P., Jackson, R., Voorhees, D. & Christy, J. (1980). Male rape victims: Noninstitutionalized assault. *American Journal of Psychiatry*, 137 (2), 221-223.

Kaur, S., Krishan, K. Chatterjee, P.M. & Kanchan, T. (2013). Analysis and identification of bite marks in forensic casework. *Oral Health and Dental Management*, 12 (3), 127-131.

Kilpatrick, D.G., Resnick, H.S., Ruggiero, K.J., Conoscenti, M.A. & McCauley, J. (2007). *Drug-facilitated, incapacitated, and forcible rape: A national study*. Final report for National Institute of Justice, grant number 2005-WG-BX-0006. NCJ 219181, available at <http://www.ncjrs.gov>.

Klein, A., Krebs, O., Gehl, A., Morgner, J., Reeger, L., Augustin, C. & Edler, C. (2018). Detection of blood and DNA traces after thermal exposure. *International Journal of Legal Medicine*, 132 (4), 1025-1033.

Koss, M. (2006). Restoring rape survivors: Justice, advocacy and a call to action. *Annals of the New York Academy of Sciences*, 1087, 206-234.

Krug, E.G., Dahlberg, L.L., Mercy, J.A., Zwi, A.B. & Lozano, R. (Eds.). (2002). [World report on violence and health](#). Geneva, Switzerland: World Health Organization.

Larsen, M.L. & Hilden, M. (2016). Male victims of sexual assault: 10 years' experience from a Danish sexual assault center. *Journal of Forensic and Legal Medicine*, 43, 8-11.

Lauber, A.A. & Souma, M.L. (1982). Use of toluidine blue for documentation of traumatic intercourse. *Obstetrics and Gynecology*, 60 (5), 644-648.

Lewis, C. & Marroquin, L.A. (2015). Effects of skin elasticity on bite mark distortion. *Forensic Science International*, 257, 293-296.

Lincoln, C., Perera, R., Jacobs, I. & Ward, A. (2013). Macroscopically detected female genital injury after consensual and non-consensual vaginal penetration: A prospective comparison study. *Journal of Forensic and Legal Medicine*, 20 (7), 884-901.

Linden, J.A. (2011, corrected 2012). Care of the adult patient after sexual assault. *New England Journal of Medicine*, 365, 834-831.

Lindsay, S. (1998). An epidemiological study of the influence of victim age and relationship to the suspect on the results of evidentiary examinations and law enforcement outcomes in cases of reported sexual assault (Unpublished doctoral dissertation). San Diego State University, San Diego, California.

Littel, K. (2001, April). [Sexual Assault Nurse Examiner \(SANE\) programs: Improving the community response to sexual assault victims](#). *OVC Bulletin*. Washington, DC: Office for Victims of Crime, US Department of Justice.

Lonsway, K.A. & Archambault, J. (2012). The 'justice gap' for sexual assault cases: Future directions for research and reform. *Violence Against Women*, 18, 145-168.

Lovell, R. Luminais, M., Flannery, D.J., Bell, R. & Kyker, B. (2018). Describing the process and quantifying the outcomes of the Cuyahoga County sexual assault kit initiative. *Journal of Criminal Justice*, 57, 106-115.

Markowitz, J. (2010, December). [The prosecutor's reference: Medical forensic examination and the role of SANEs in cases involving adult victims](#). AEquitas: The Prosecutors' Resource on Violence Against Women.

Markowitz, J. (2017). [Understanding genital injury in sexual assault cases](#) [PDF document].

Markowitz, J. & Scalzo, T. (2011). [Understanding anogenital injury in adult sexual assault cases](#). AEquitas *Strategies in Brief*, 5.

Mason, F. & Lodrick, Z. (2013). Psychological consequences of sexual assault. *Best Practice & Research Clinical Obstetrics & Gynaecology*, 27 (1), 27-37.

McEwen, T. (2011). *The role and impact of forensic evidence in the criminal justice process*. Final report for National Institute of Justice, grant number 2006-DN-BX-0095. NCJ 236474, available at <http://www.ncjrs.gov>

Mcguown, C., Frey, J., Steer, S., Fletcher, G.E., Kinkopf, B., Fakler, M. & Prulhiere, V. (2016). Prevalence of strangulation in survivors of sexual assault and domestic violence. *American Journal of Emergency Medicine*, 34 (7), 1281-1285.

McLean, I., Roberts, S.A., White, C. & Paul, S. (2011). Female genital injuries resulting from consensual and non-consensual vaginal intercourse. *Forensic Science International*, 204 (1-3), 27-33.

Morgan, L., Dill, A. & Welch, J. (2011). Sexual assault of postmenopausal women: a retrospective review. *BJOG: An International Journal of Obstetrics and Gynaecology*, 118 (7), 832-843.

Nash, K. & Sheridan, D. (2009). Can one accurately date a bruise? State of the science. *Journal of Forensic Nursing*, 5 (1), 31-37.

National Judicial Education Program (2002). Understanding sexual violence: Prosecuting adult rape and sexual assault cases (Participant material). From [Presenting medical evidence in an adult rape trial](#) [Video library, Volume I]. Legal Momentum: The Women's Legal Defense and Education Fund.

National Institute of Justice (NIJ) and the Sexual Assault Forensic Evidence Reporting (SAFER) Working Group. (2016). [National best practices for sexual assault kits: A multidisciplinary approach](#).

Office on Violence Against Women (2016). [National protocol for sexual abuse medical forensic examinations - Pediatric](#). Washington, DC: US Department of Justice, Office on Violence Against Women.

Office on Violence Against Women (2013). [National protocol for sexual assault medical forensic examinations - Adult/adolescent](#). Washington, DC: US Department of Justice, Office on Violence Against Women.

Palmer, C.M., McNulty, A.M, D'Este, C. & Donovan, B. (2004). Genital injuries in women reporting sexual assault. *Sexual Health*, 1 (1), 55-59.

Patterson, D., & Campbell, R. (2012). The problem of untested sexual assault kits: Why are some kits never submitted to a crime laboratory? *Journal of Interpersonal Violence*, 27 (11), 2259-2275.

Peterson, J., Sommers, I., Baskin, D. & Johnson, D. (2010). *The role and impact of forensic evidence in the criminal justice process*. Final report for National Institute of Justice, grant number 2006-DN-BX-0094. NCJ 231977, available at <http://www.ncjrs.gov>

Pierce-Weeks, J. (2013). [Sexual violence in later life: A technical assistance guide for health care providers](#). Enola, PA: National Sexual Violence Resource Center.

Poarch, J. & Faugno, D. (2017). Adult male sexual assault. In A.P. Giardino, D.K. Faugno, M.J. Spencer, M.L. Weaver & P.M. Speck, P.M. (Eds.), *Sexual assault: Victimization across the life span* (pp. 157-168). Florissant, MO: STM Learning, Inc.

Poulos, C. & Sheridan, D. (2008). Genital injuries in postmenopausal women after sexual assault. *Journal of Elder Abuse and Neglect*, 20 (4), 323-335

Riggs, N., Houry, D., Long, G., Markovchick, V. & Feldhaus, K.M. (2000). Analysis of 1,076 cases of sexual assault. *Annals of Emergency Medicine*, 35 (4), 358-362.

Riviello, R. (2013). [Bite mark guidelines](#). In American College of Emergency Physicians (Ed.), *Evaluation and management of the sexually assaulted or sexually abused patient* (2nd ed.).

Riviello, R. (2014, February 6). [Can you tell how old this bruise is based on its color?](#) *ACEP Now*.

Rosay, A.B. & Henry, T. (2008). Final report: Alaska sexual assault nurse examiner study. Final report for National Institute of Justice, grant number 2004-WG-BX-0003.

Ruxana, J., Jewkes, R., Vetten, L., Christofides, N., Sigsworth, R. & Loots, L. (2015). Genito-anal injury patterns and associated factors in rape survivors in an urban province of South Africa: A cross-sectional study. *BMC Women's Health*, 15, 29.

Ruxana, J. & Thomas, L. (2013). Health consequences of sexual violence against women. *Best Practice & Research Clinical Obstetrics & Gynaecology*, 27 (1), 15-26.

Sachs, C.J., & Chu, L.D. (2002). Predictors of genitorectal injury in female victims of suspected sexual assault. *Academic Emergency Medicine*, 9 (2), 146-151.

Shelton, D.E. (2010). Juror expectations for scientific evidence in criminal cases: Perceptions and reality about the 'CSI effect' myth. *Thomas M. Cooley Law Review*, 27 (1), 1-35.

Sheridan, D.J. (1993). The role of the battered woman's specialist. *Journal of Psychosocial Nursing*, 31 (11), 31-37.

Sheridan, D. & Anderson, J. (2012). Female genital injury following consensual and nonconsensual sex: State of the science. *Journal of Emergency Nursing*, 38 (6), 518-522.

Shields, L.B., Corey, T.S., Weakley-Jones, B. & Stewart, D. (2010). Living victims of strangulation: A 10-year review of cases in a metropolitan community. *The American Journal of Forensic Medicine and Pathology*, 31 (4), 320-325.

- Slaughter, L. (2013). Sexual assault. In R. Walls, R. Hockberger & M. Gausche-Hill (Eds.), *Rosen's emergency medicine – Concepts and clinical practice* (pp. 800-814). Philadelphia, PA: Elsevier.
- Slaughter, L. & Brown, C.R.V. (1992). Colposcopy to establish physical findings in rape victims. *American Journal of Obstetrics and Gynecology*, 166 (1 Pt 1), 83-86.
- Slaughter, L., Brown, C.R.V., Crowley, S. & Peck, R. (1997, March). Patterns of genital injury in female sexual assault victims. *American Journal of Obstetrics and Gynecology*, 176 (3), 609-616.
- Sommers, M. (2007). Defining patterns of genital injury from sexual assault: A review. *Trauma, Violence, & Abuse*, 8 (3), 270-280.
- Sommers, M., Fargo, J., Baker, R., Fisher, B., Buschur, C. & Zink, T. (2009). Health disparities in the forensic sexual assault examination related to skin color. *Journal of Forensic Nursing*, 5 (4), 191-200.
- Sommers, M., Schafer, J., Zink, T., Hutson, L. & Hillard, P. (2001). Injury patterns in women resulting from sexual assault. *Trauma, Violence, & Abuse: A Review Journal*, 2 (3), 240-258.
- Sommers, M., Zink, T., Baker, R., Fargo, J., Porter, J., Weybright, D. & Schafer, J. (2006). The effects of age and ethnicity on physical injury from rape. *Journal of Obstetric, Gynecologic, and Neonatal Nursing*, 35 (2), 199-207.
- Sommers, M., Zink, T., Fargo, J., Baker, R., Buschur, C., Shambley-Ebron, D. & Fisher, B. (2008). Forensic sexual assault examination and genital injury: Is skin color a source of disparity? *American Journal of Emergency Medicine*, 26 (8), 857-866.
- Speck, P. & Ballantyne, J. (2015) [Post-coital DNA recovery study](#). Final report for National Institute of Justice, grant number 2009-DN-BX-0023. NCJ 248682, available at <http://www.ncjrs.gov>
- Spohn, C. & Tellis, K.M. (2012). *Policing and prosecuting sexual assault in Los Angeles City and County: A collaborative study in partnership with the Los Angeles Police Department, the Los Angeles County Sheriff's Department, and the Los Angeles County District Attorney's Office*. Final Report for National Institute of Justice, grant number 2009-WG-BX-0009. NCJ 237582, available at <http://www.ncjrs.gov>
- Sugar, N.F., Fine, D.N. & Eckert, L.O. (2004). Physical injury after sexual assault: Findings of a large case series. *American Journal of Obstetrics and Gynecology*, 190 (1), 71-76.
- Technical Working Group on Biological Evidence Preservation (2013). [The biological evidence preservation handbook: Best practices for evidence handlers](#). Washington, DC: US Department of Justice, National Institute of Standards and Technology, NISTIR 7928.



US Department of Defense [DoD]. [Suspect instructions: DoD sexual assault evidence collection kit and DD form 2911](#). Washington, DC: Author.

Valentine, J. & Miles, S. (2014). *Current research findings in sexual assault cases in Utah & implications on practice* (slide presentation). Results of National Institute of Justice (NIJ) Study.

White, C. & McLean, I. (2006). Adolescent complaints of sexual assault: Injury patterns in virgin and non-virgin groups. *Journal of Clinical Forensic Medicine*, 13 (4), 172-180.

Williams, K.S. & Bierie, D.M. (2015). An incident-based comparison of female and male sexual offenders. *Sexual Abuse: A Journal of Research and Treatment*, 27 (3), 235-257.

Zilkens, R.R., Phillips, M.A., Kelly, M.C., Mukhtar, S.A., Semmens, J.B. & Smith, D.A. (2016). Non-fatal strangulation in sexual assault: A study of clinical and assault characteristics highlighting the role of intimate partner violence. *Journal of Forensic and Legal Medicine*, 43, 1-7.

Zilkens, R.R., Smith, D.A., Kelly, M.C., Mukhtar, S.A., Semmens, J.B. & Phillips, M.A. (2017). Sexual assault and general body injuries: A detailed cross-sectional Australian study of 1163 women. *Forensic Science International*, 279, 112-120.

Zilkens, R.R., Smith, D.A., Phillips, M.A., Mukhtar, S.A., Semmens, J.B. & Kelly, M.C. (2017). Genital and anal injuries: A cross-sectional Australian study of 1266 women alleging recent sexual assault. *Forensic Science International*, 275, 195-202.

Zink, T., Fargo, J., Baker, R., Buschur, C., Fisher, B. & Sommers, M. (2010). Comparison of methods for identifying ano-genital injury after consensual intercourse. *Journal of Emergency Medicine*, 39 (1), 113-118.

Zinzow, H.M, Resnick, H.S., Barr, S.C., Danielson, C.K. & Kilpatrick, D.G. (2012). Receipt of post-rape medical care in a national sample of female victims. *American Journal of Preventive Medicine*